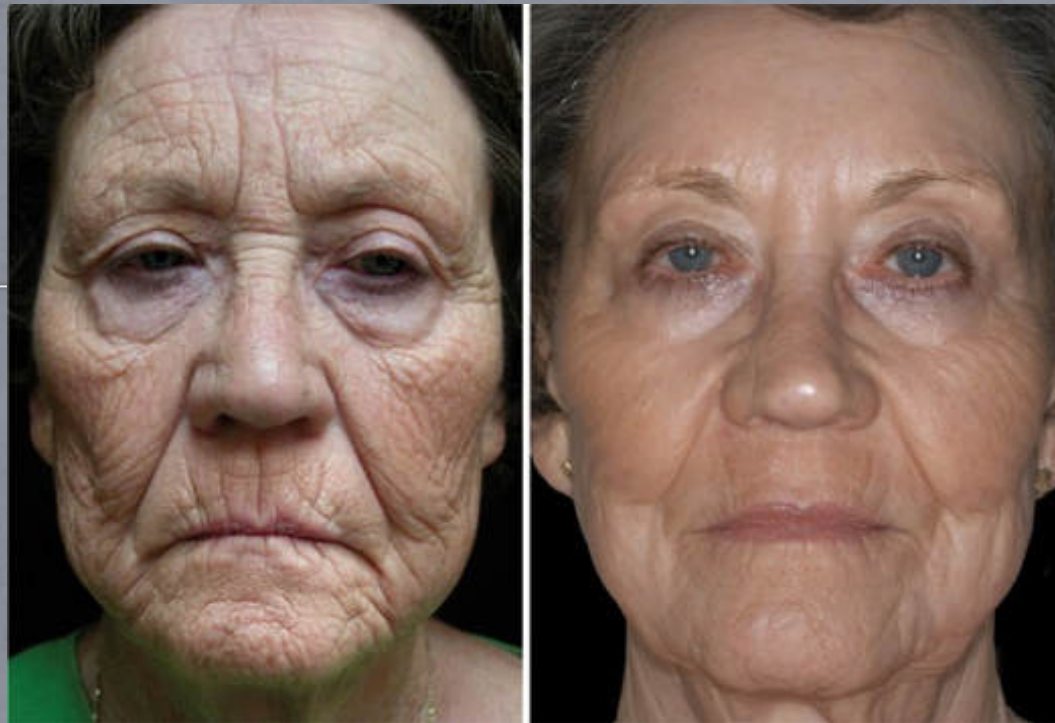

Non-Surgical Therapeutics for the Eyelids

Kimberly Cockerham, MD, FACS



Kimberly Cockerham, MD, FACS

- Associate Clinical Professor, Stanford University
- Palo Alto VA



- Private Practice
 - Zeiter Eye Medical Group, Inc.
www.CockerhamMD.com

Financial Disclosures

YourSkinSpace.com (O)

Lumenis (L)

Pfizer (R)

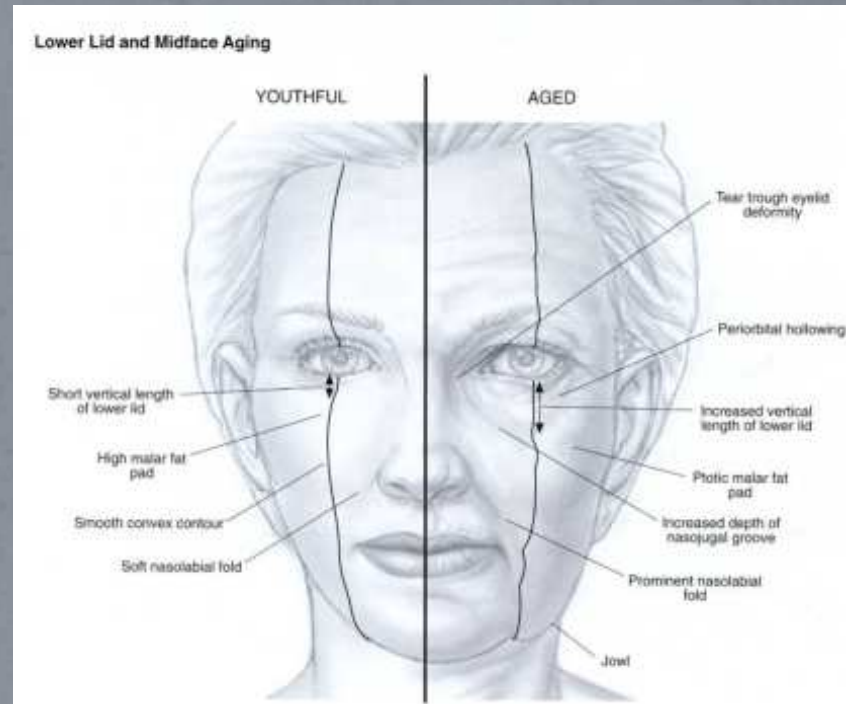
Galderma, Activatek, FanMinder

Renovo, Excalliard, DoctorBase, 3T ophthalmics (C)

Department of Defense Grant (R)

Full, Firm and Luminous Eyelids

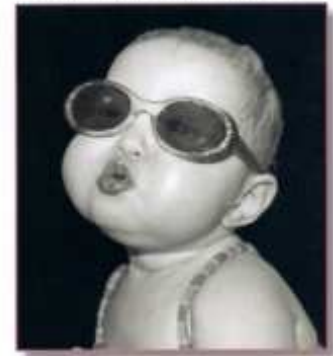- Topicals
 - Vit C
 - Hyaluronic acid
 - Micronized zinc
 - Prescriptives
- Adjuncts
 - Clarisonic brush
- Injectables
 - Botox and Dysport
 - Dermal fillers
- Laser options
 - Erbium and Thermage don't work
 - Fractionated CO₂ best option



Why Skin Glows....

“

This is the strangest life I have ever known.



John Martson (1943-1971)

”

- Luminosity...
 - Light is reflected from the skin
 - A smooth, well exfoliated, surface reflects light directly back at the viewer
- As we age skin cell turn over slows... the skin surface looks dull due to scattered light

Anti-Aging Eyelid Protocol - Morning

- Clarisonic brush
- Vitamin C and E serum or cream
- Hyaluronic acid
- Sunblock – Micronized Zinc Brush



Clarisonic Brush

- Sonic frequency > 300 per second
- Indications:
 - Loosens dirt and oil
 - Eliminates pollution
 - Cleans pores
 - Removes make-up



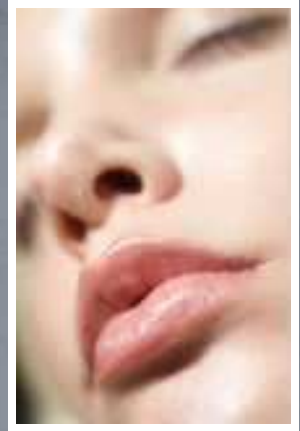
The Power of Vitamin C

- Neutralize free-radicals
- Suppresses inflammation
- Prevents skin cells from oxidizing prematurely
- After exfoliating and under sun protection




Topical Hyaluronic Acid

- Smooths wrinkles
- Moisturizes skin
- Anti-aging



Realistic Sun Protection

- Chemical
 - Parasol (Jan Marini)
 - Helioplex (neutrogena)
- Get Physical
 - Zinc Oxide
 - Titanium Oxide
- Advanced skin protection
 - UVA and UVB Windshield coating
 - Micronized zinc clothing
 - **Micronized zinc topical**



Latisse



- First FDA-approved treatment to grow longer, thicker, darker eyelashes
- Users may experience itching, dryness, or redness of the eye, or hyperpigmentation of the skin along the lash line
- ? iris pigmentation
- Results at 12-16 weeks

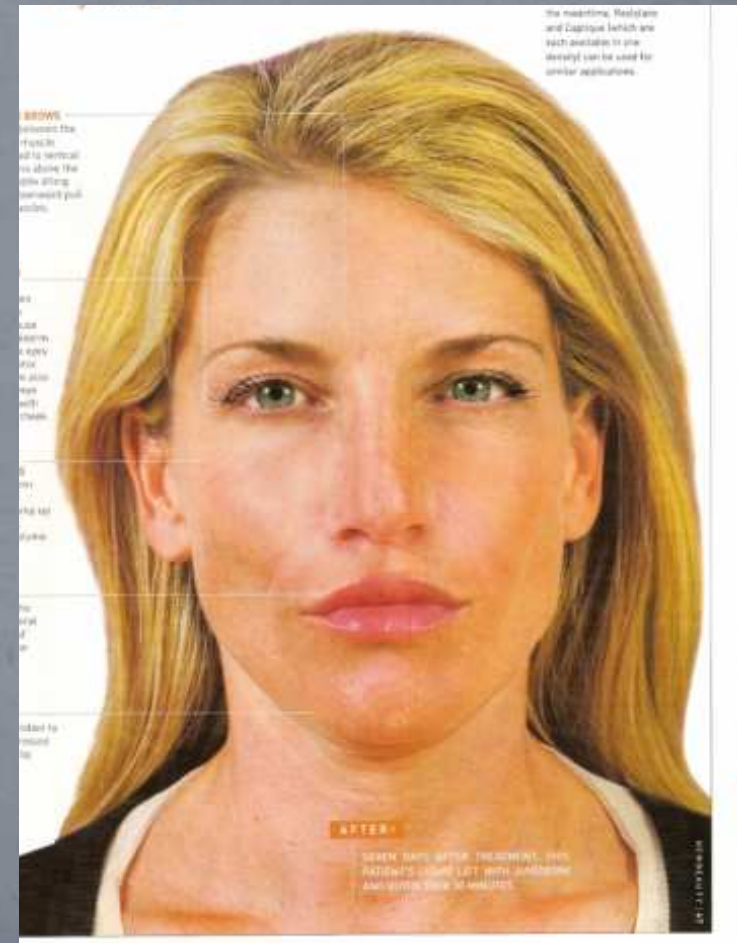

A New Option for Eyelid Rejuvenation



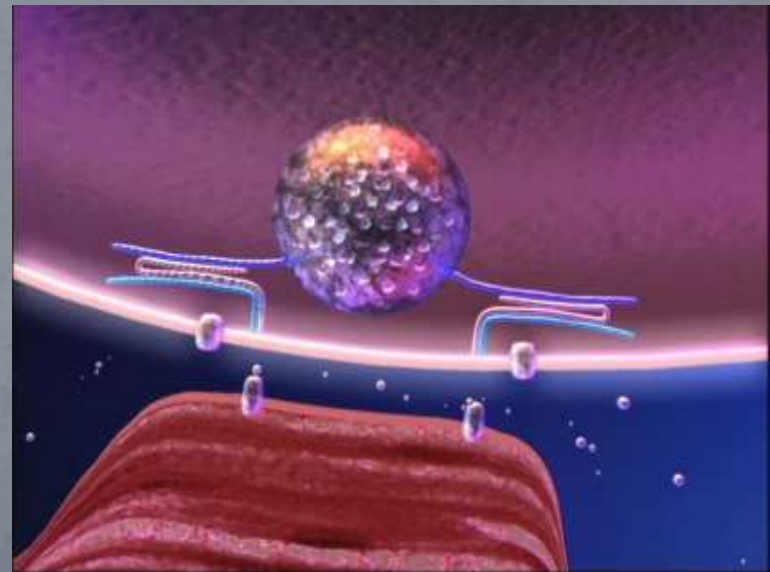
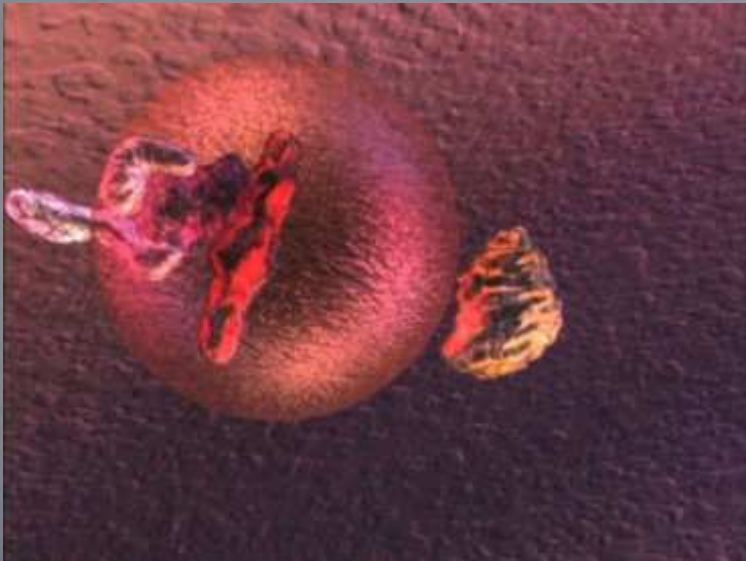
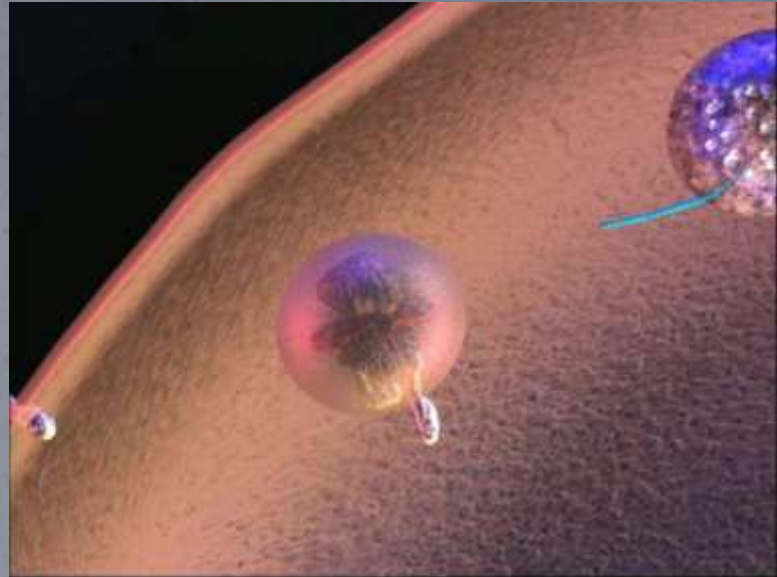
www.EyeEco.com

Botox + Filler = Liquid Facelift Before and After

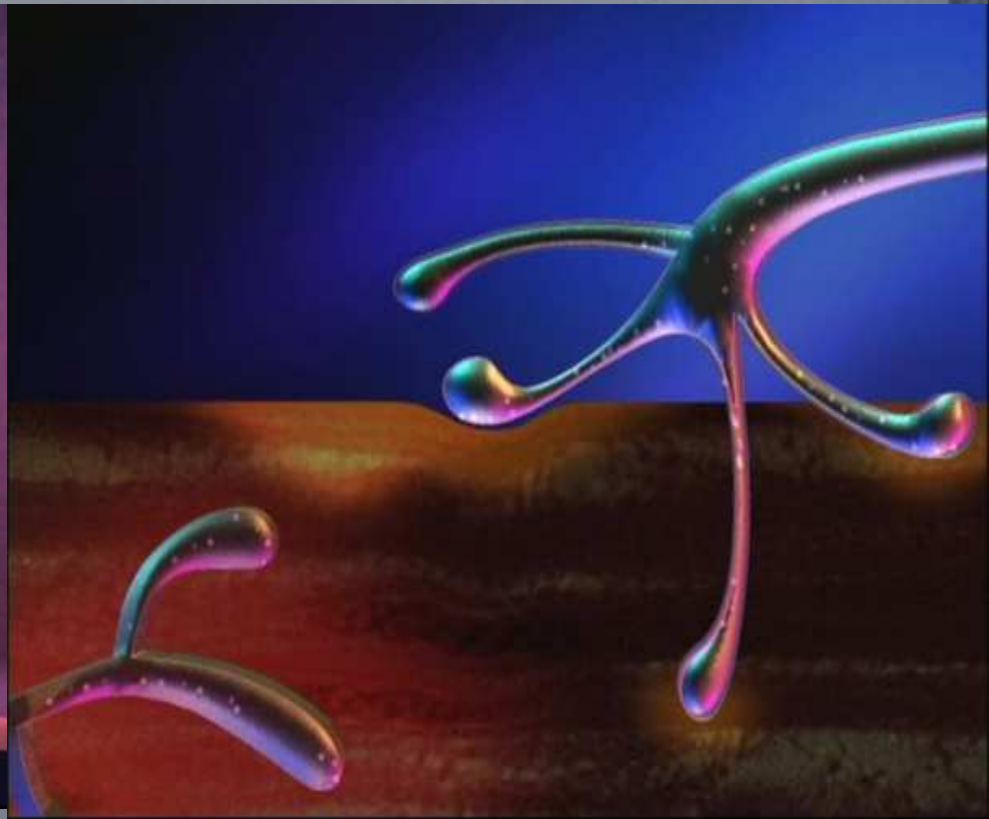
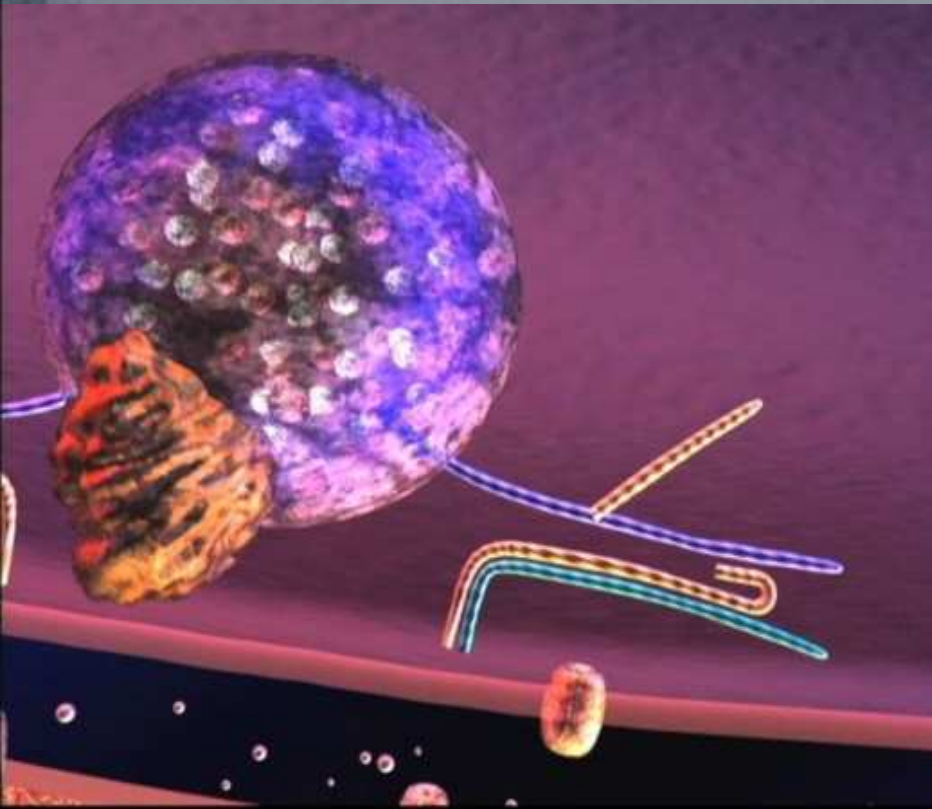


Age 42: no surgery / no laser

My Favorite Purified Protein.....



BOTOX is internalized by endocytosis
Light Chain is released into cytoplasm
BOTOX[®] cleaves SNAP 25 & prevents Ach release
Sprouting recurs at approx 3 months



Botulinum A

Indications for Use

- Cosmetic
- Eyelid spasms
- Eyelid Retraction
 - Thyroid eye disease
 - Seventh nerve palsy
- Ptosis
- Entropion/trichiasis

BROW POSITION AND BROW SHAPE IN THE UPPER FACE



Sadness
Fatigue
Anxiety



Unhappy
Anger
Fatigue

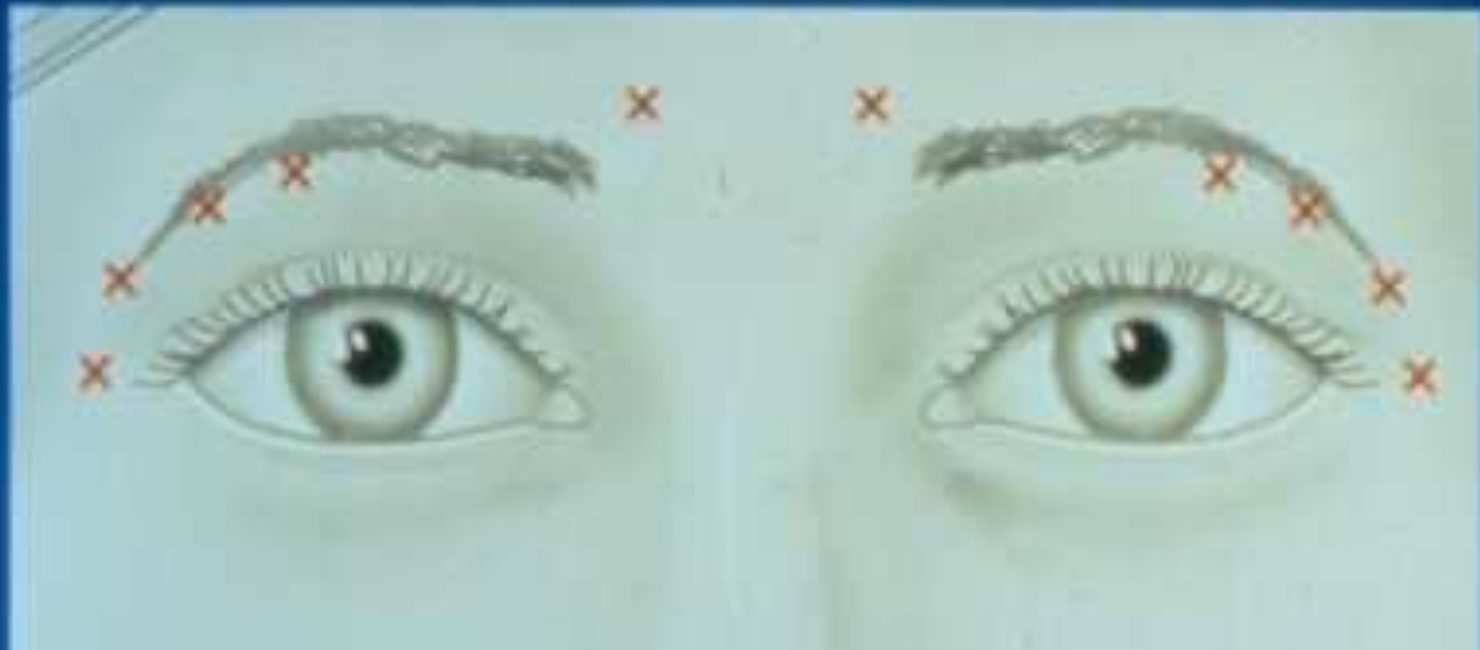


Ideal
brow?

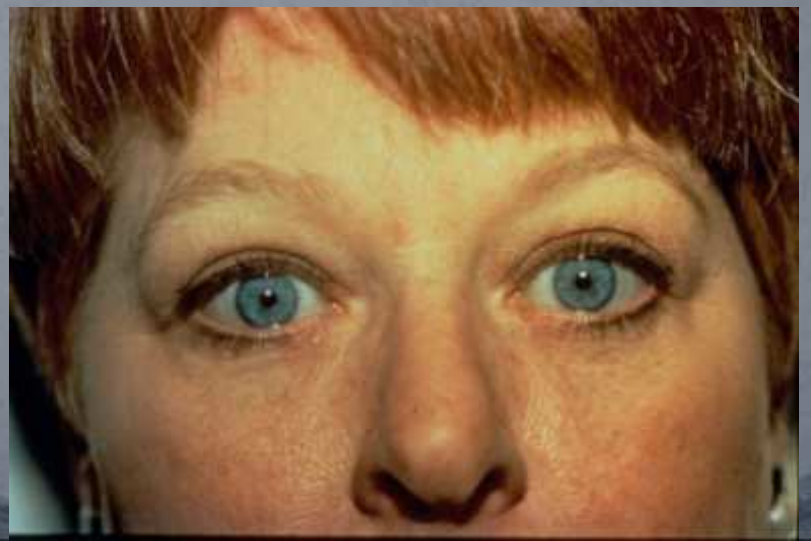
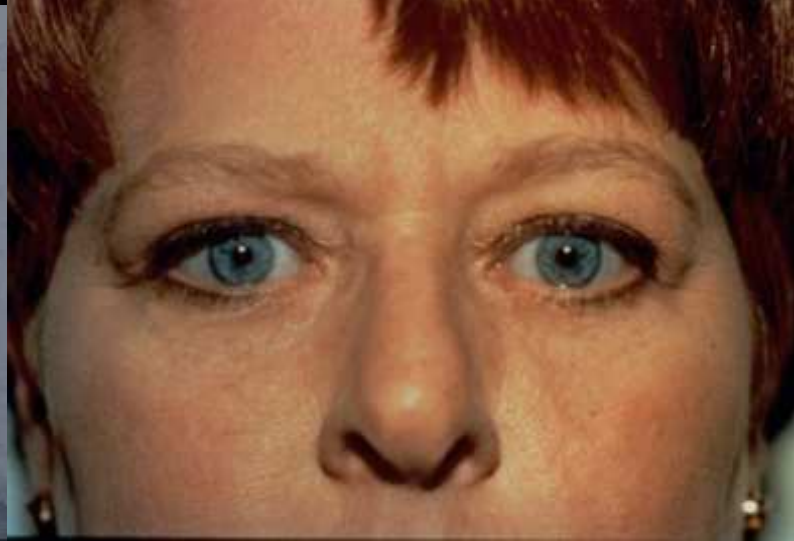
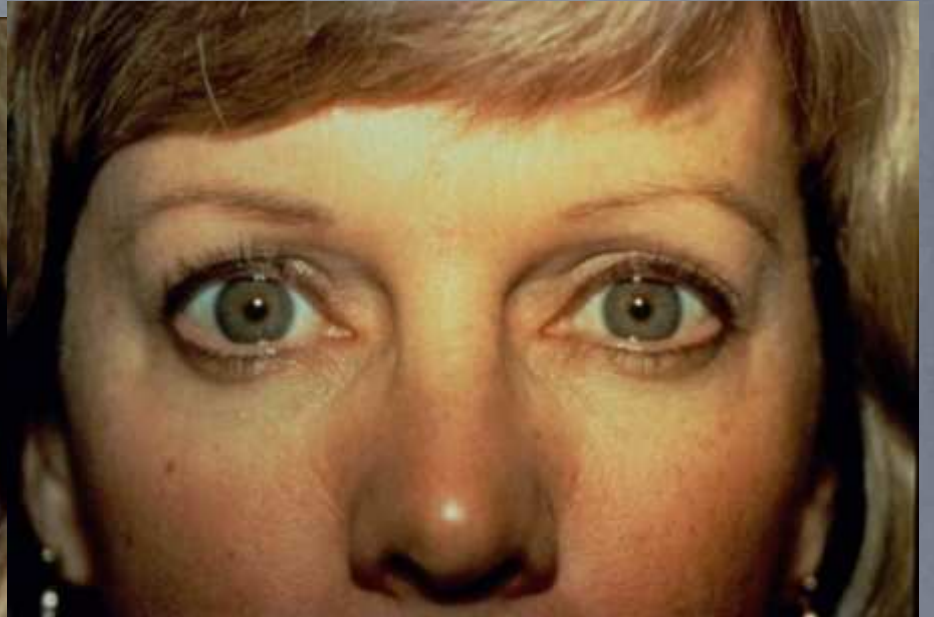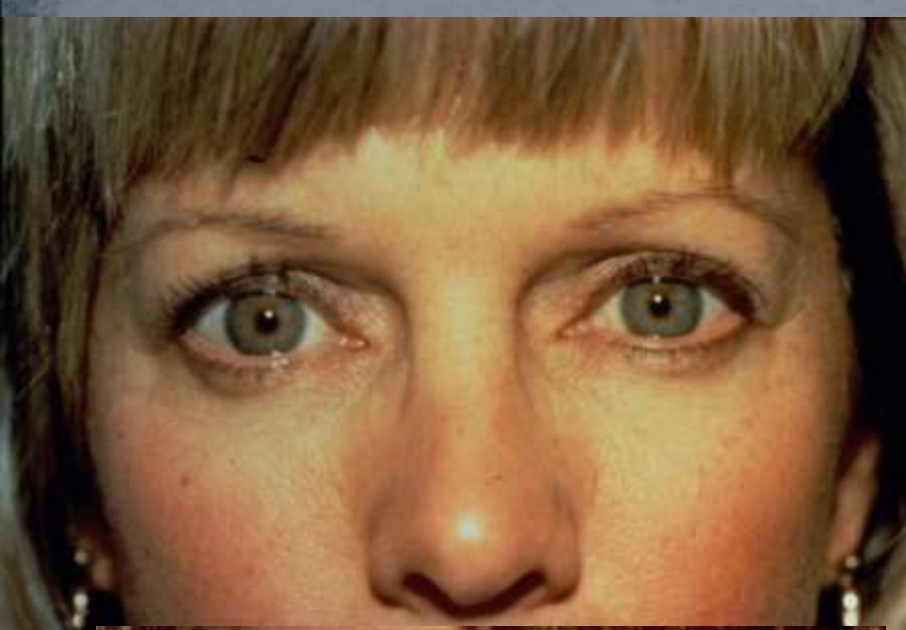BOTOX Browlift

Botulinum Toxin Injection Sites

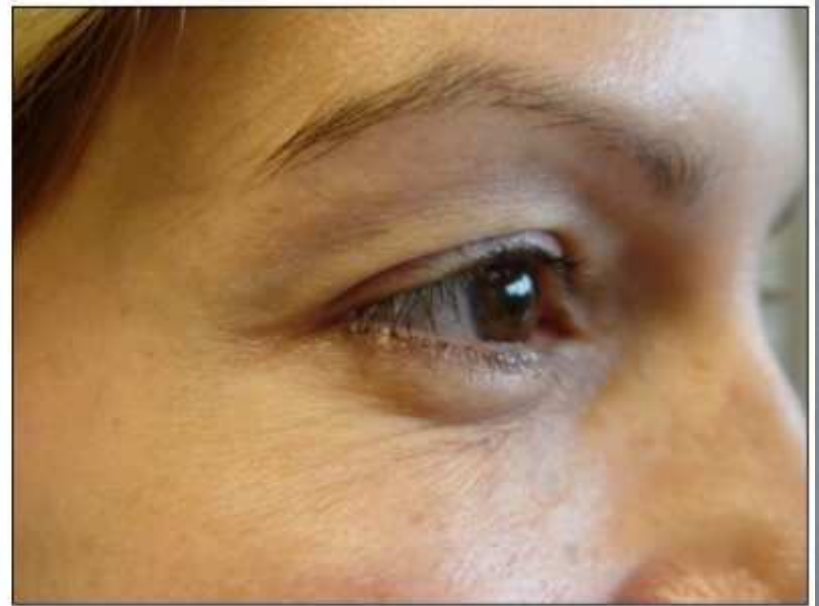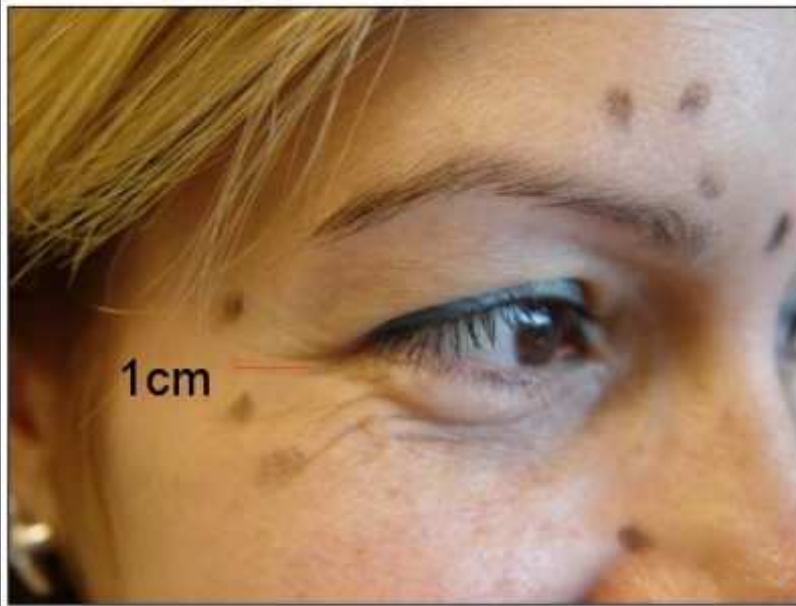


BOTOX Browlift



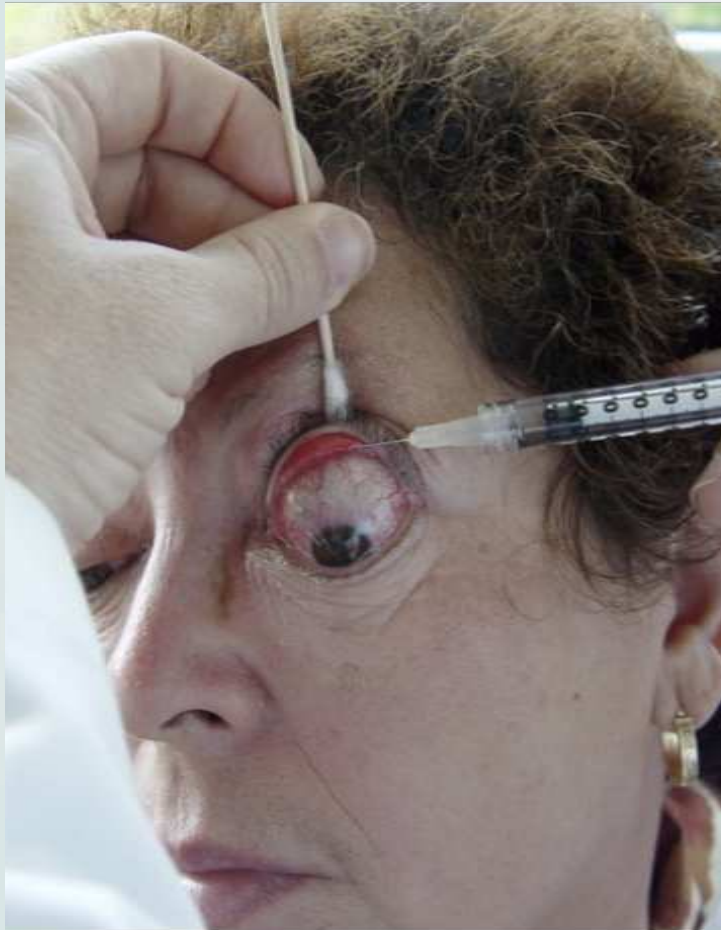CROW'S FEET

“laugh lines”



2.5 un (3 sites)

LID RETRACTION



✓ Transcutaneous or
Transconjunctival
injection

- *Over superior tarsal
border*
 - 4–6 UN

Botulinum A Ptosis 'repair'

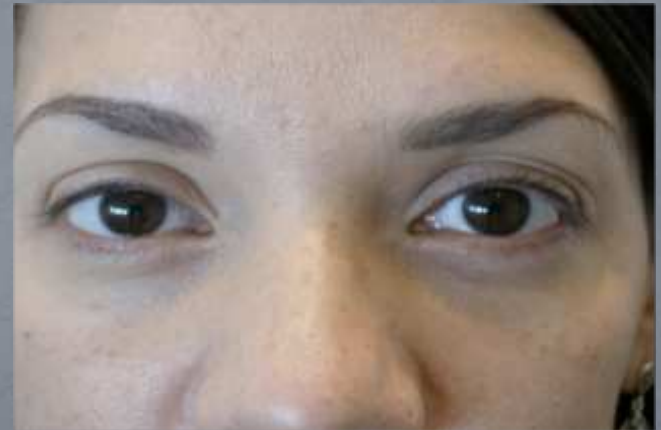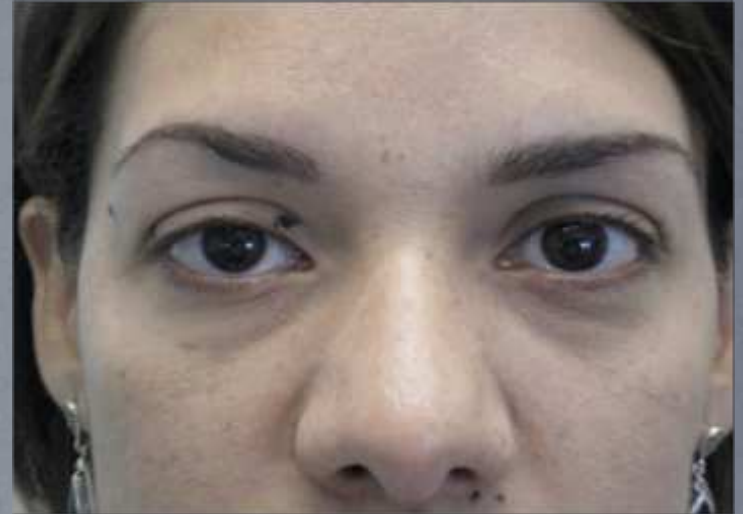Small Ptosis (*1–2
mm*)

Injection Pretarsal
Orbicularis

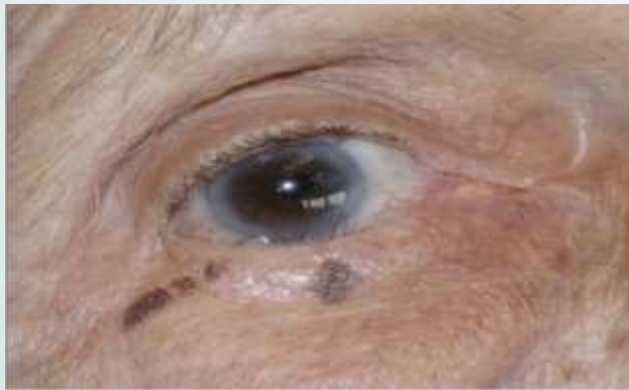
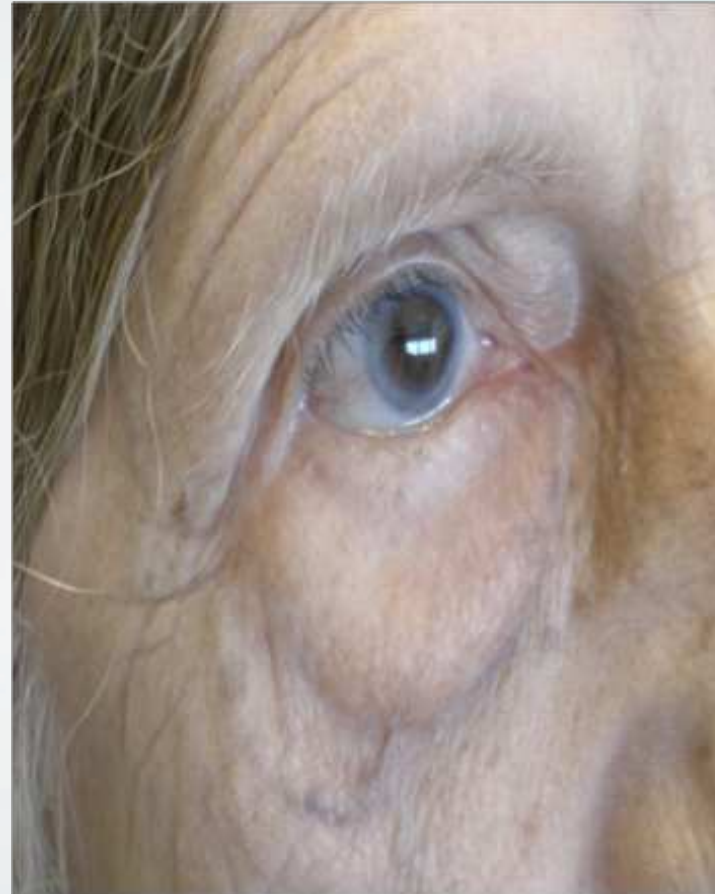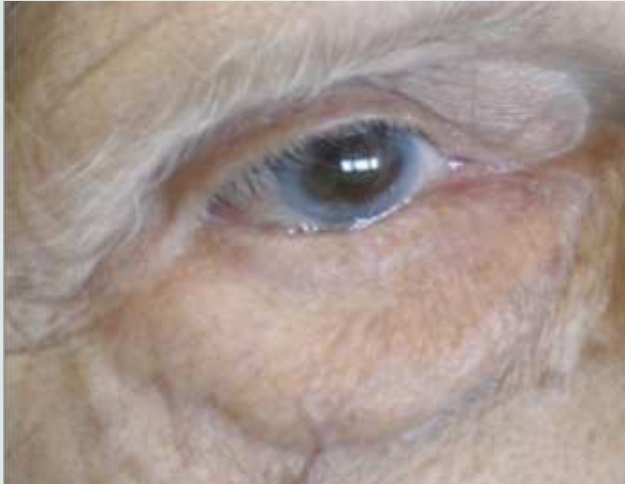1 or 2 sites

(spare center)

1.25 to 1.5 UN



ENTROPION



2-4 UN

Dermal Fillers

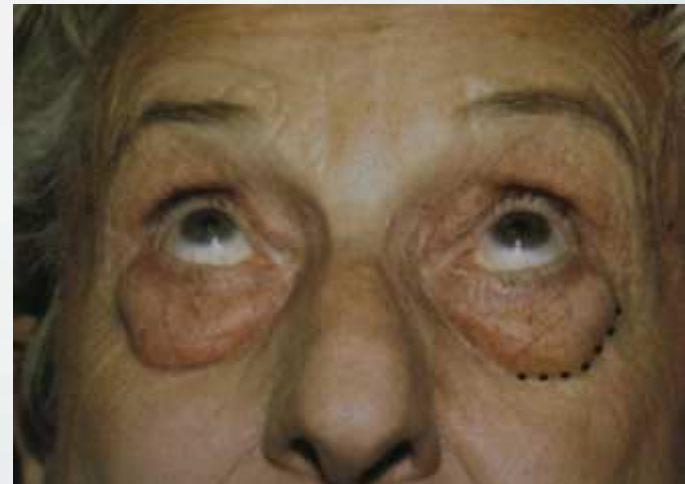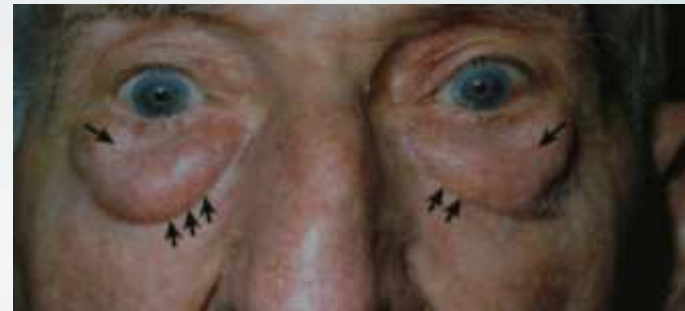- Hyaluronic Acid: Restylane
- Fat Grafting
- ? Patient's own blood: "Vampire Facelift"

Dermal Fillers; Indications

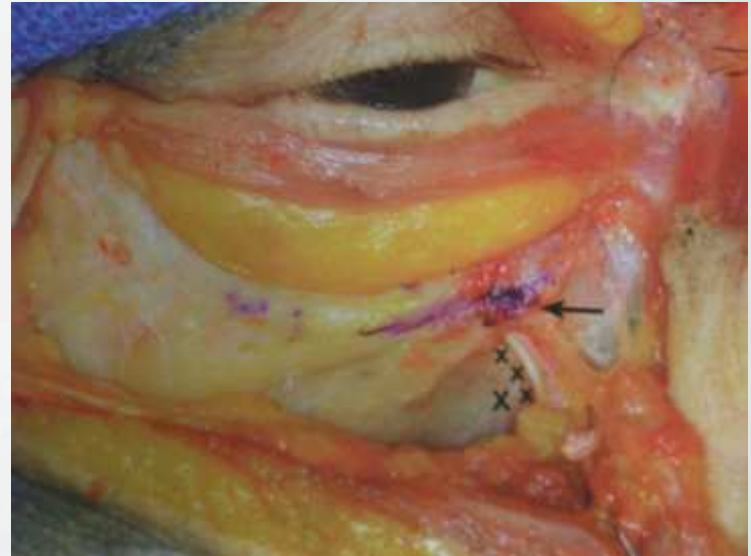
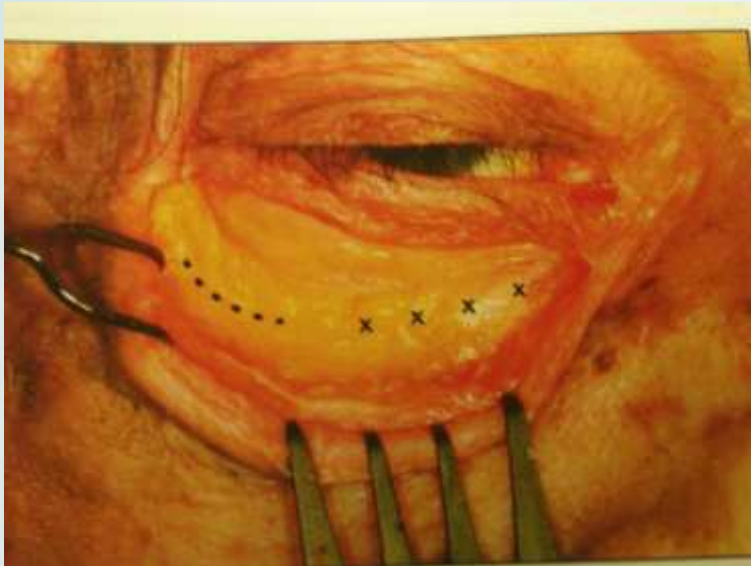
- **Functional**
 - Eyelid retraction
 - Sunken sulcus
 - Anophthalmic sockets
 - Bony defects
- **Cosmetic:**
 - Brow lift
 - Tear trough deformity
 - Lateral brow

TEAR TROUGH DEFORMITY

- Genetically mediated
- Arcus marginalis
 - defined as the confluence of the orbital septum and periosteum. Key component in this deformity pattern



TEAR TROUGH ANATOMY



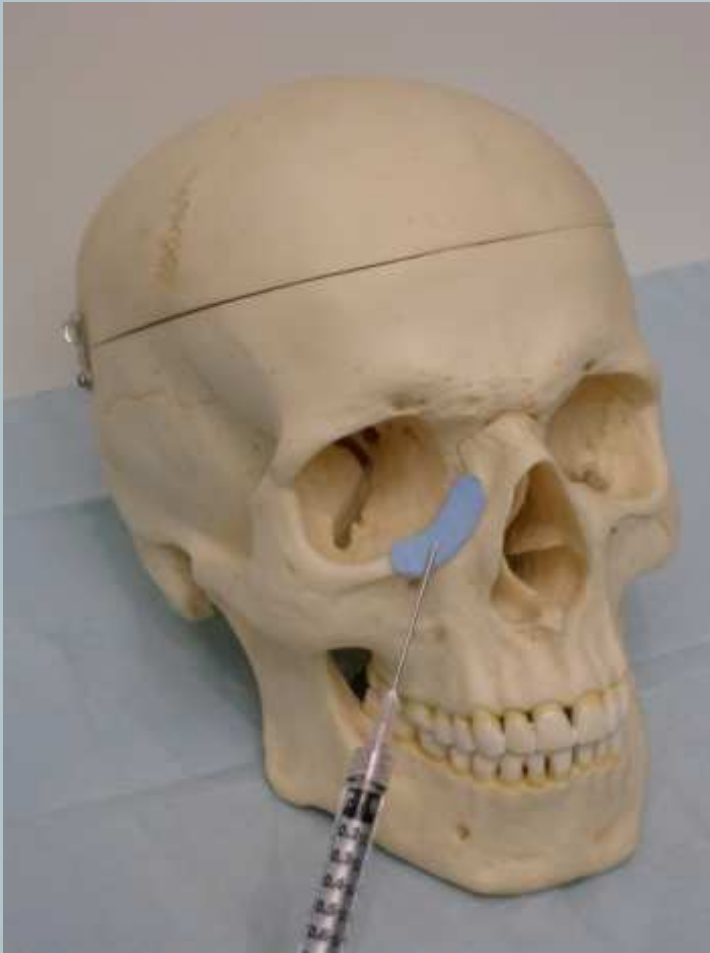
TEAR TROUGH DEFORMITY



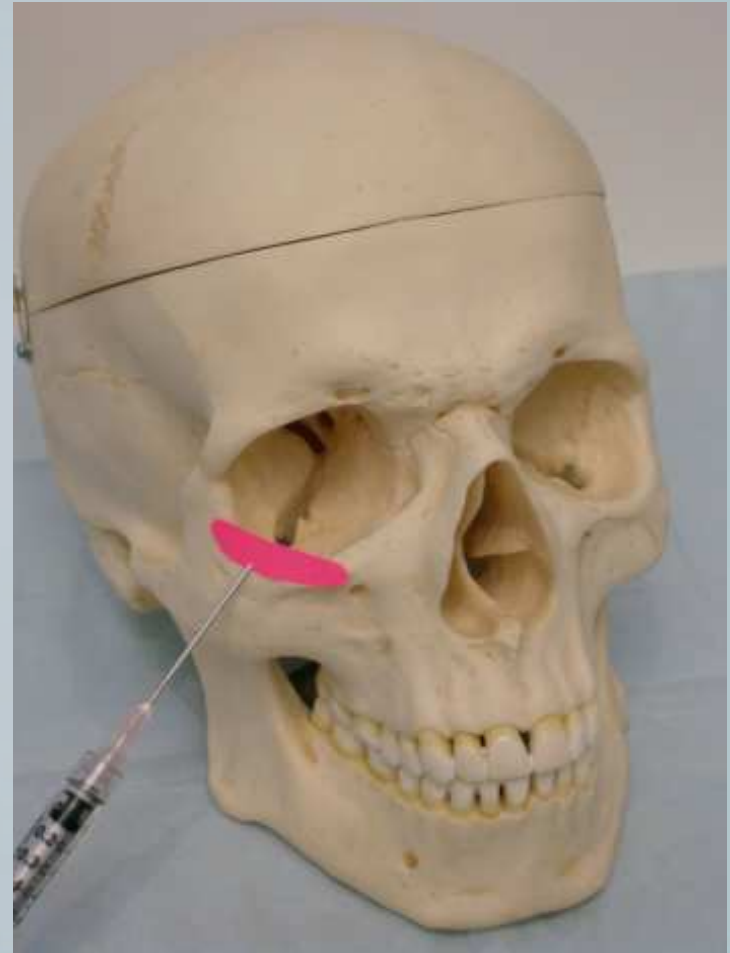
Periocular/Facial Rejuvenation–Restoration

José R. Montes,
M.D.

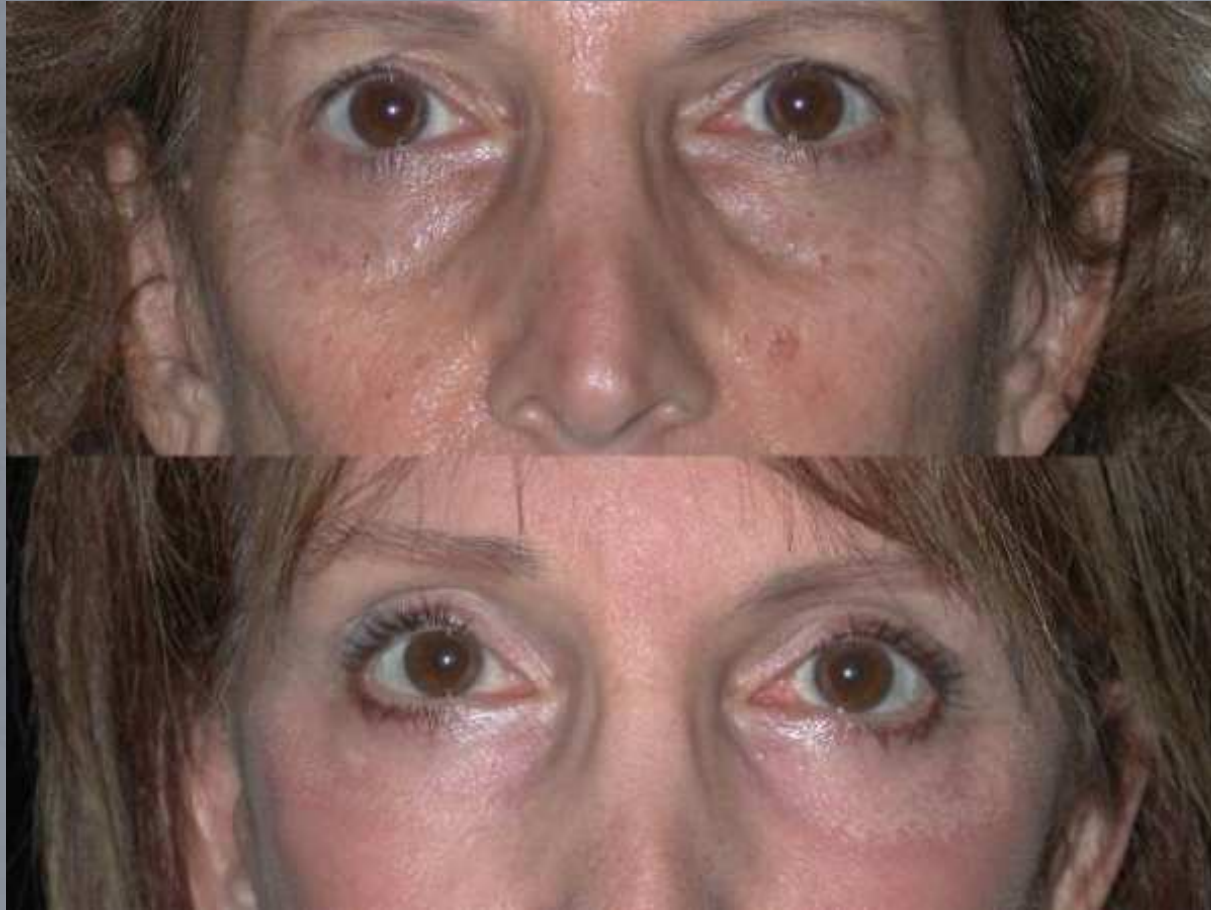TEAR TROUGH



Periocular/Facial Rejuvenation–Restoration



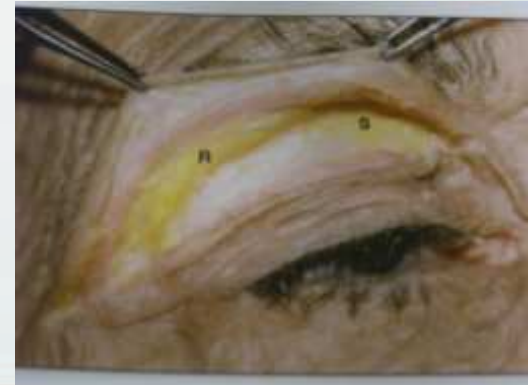José R. Montes,
M.D.



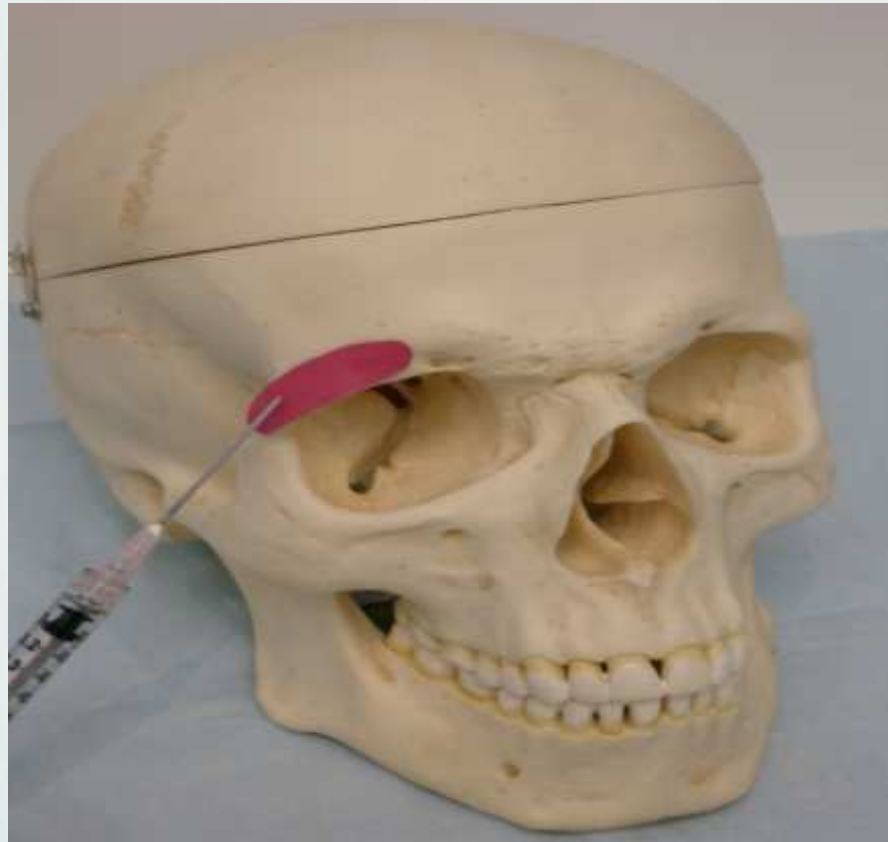ANATOMY / ROOF

Retro-orbicularis oculi fat

Below the superolateral orbicularis oculi (preseptal and orbital part) and suborbicularis fascia, but above the orbital septum, the retro-orbicularis oculi fat (ROOF) pad extends from beyond the mid-supraorbital rim to beyond the lateral orbital rim.



ROOF



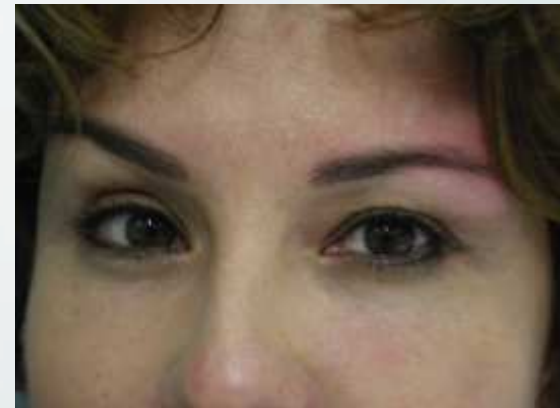Periocular/Facial Rejuvenation–Restoration

José R. Montes,
M.D.

EYEBROW ENHANCEMENT

Ideal patient:

- Women, 30s to 50s
- Arched eyebrows
- “Ideal” eyebrow height (over orbital rim)
- Injection of filler subdermal at the most lateral segment



UltraPulse Versatility

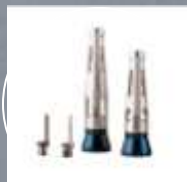Surgical Handpieces



UltraFlex
WaveGuide



TrueSpot
collimated

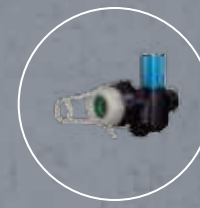

Focused
Incisional

Fractional Handpieces

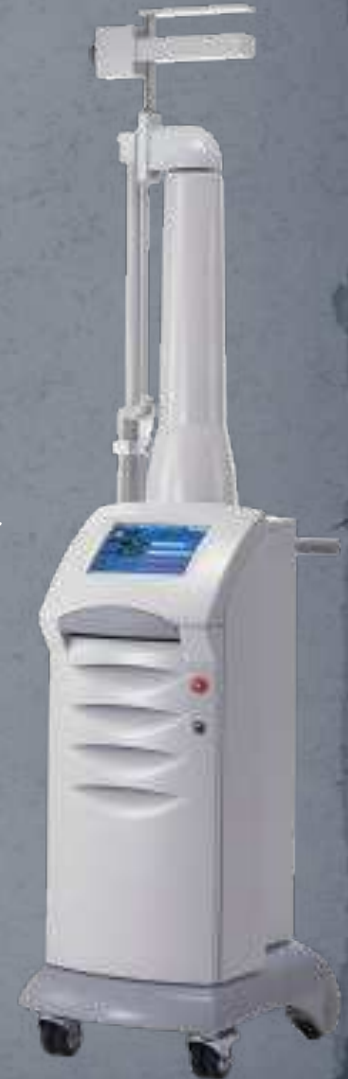

ActiveFX
UltraScan
CPG




DeepFX
Microscanner

- ▶ Wavelength: 10,600 nm (CO₂)
- ▶ Beam shape: UltraPulse
- ▶ 100s of peer reviewed publications
- ▶ Thousands of patients treated




ActiveFX™ vs. Traditional CO₂: Non-sequential Pattern Scan

Heat does not dissipate from adjacent pulses within the scan

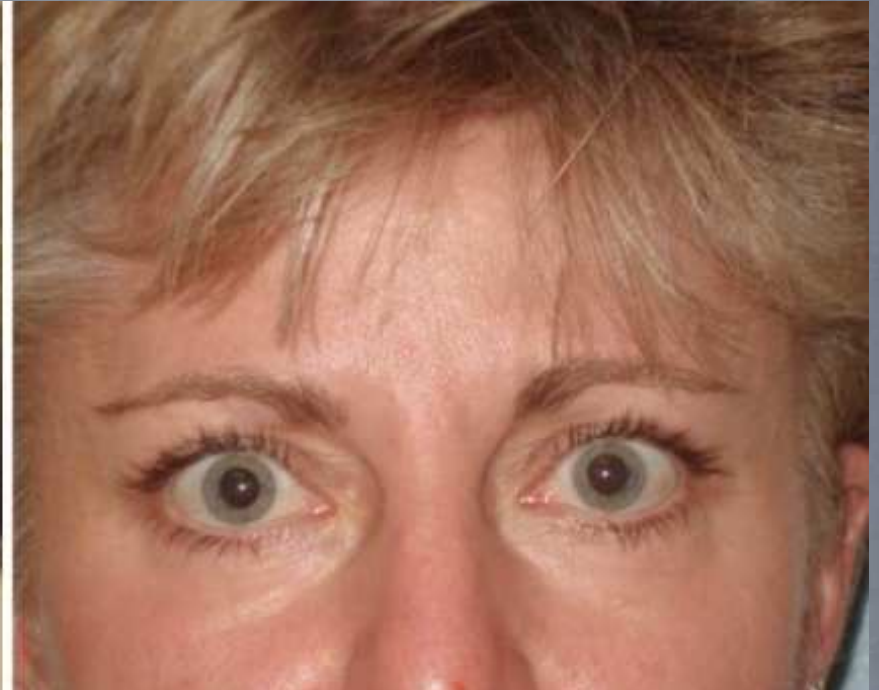

Traditional CO₂
Uses **Sequential**
Scan Sequence



CoolScan™
Non-sequential,
non-adjacent
Scan Sequence

Thermal relaxation between laser spot delivery





www.YourSkinSpace.com

Full, Firm and Luminous Eyelids

- Topicals
 - Vit C, Hyaluronic acid, Micronized zinc
 - Prescriptives
- Adjuncts
 - Clarisonic brush
- Injectables
 - Botox and Dysport
 - Dermal Fillers
- Laser options
 - Erbium and Thermage don't work
 - Fractionated CO₂ best option

Thank You!

Kimberly Cockerham, MD, FACS

www.CockerhamMD.com