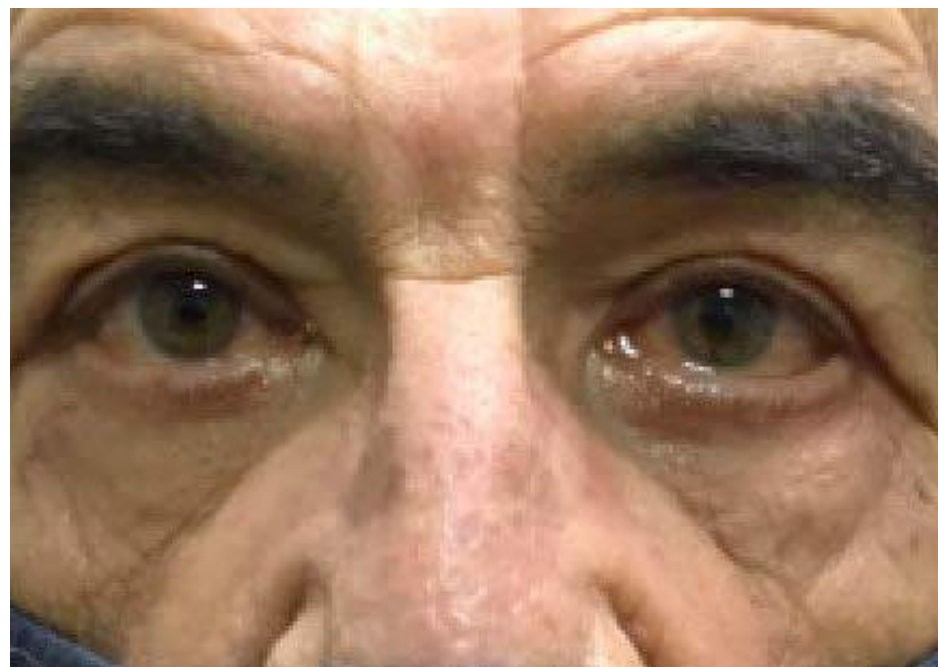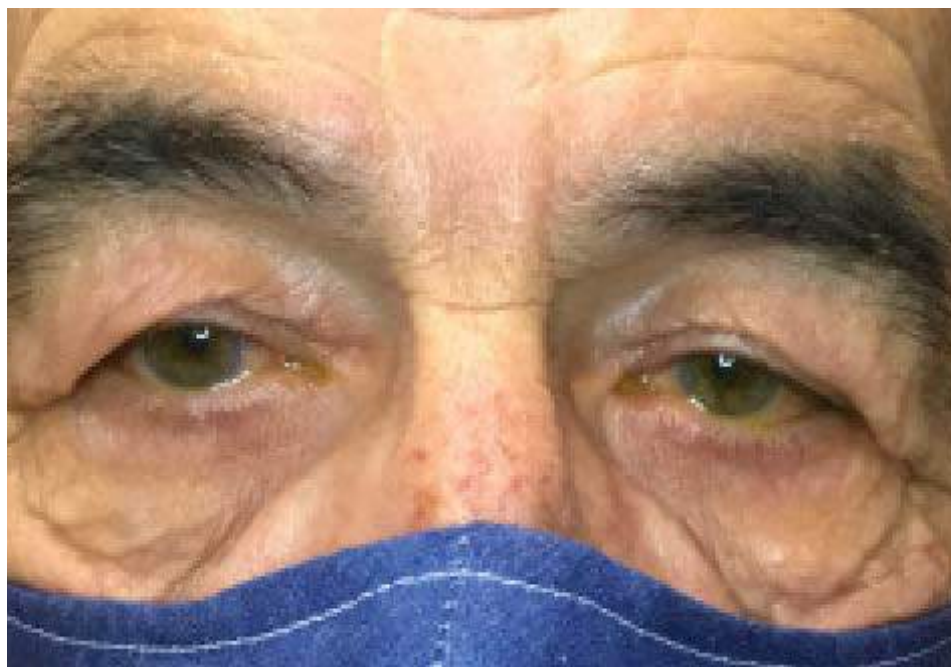



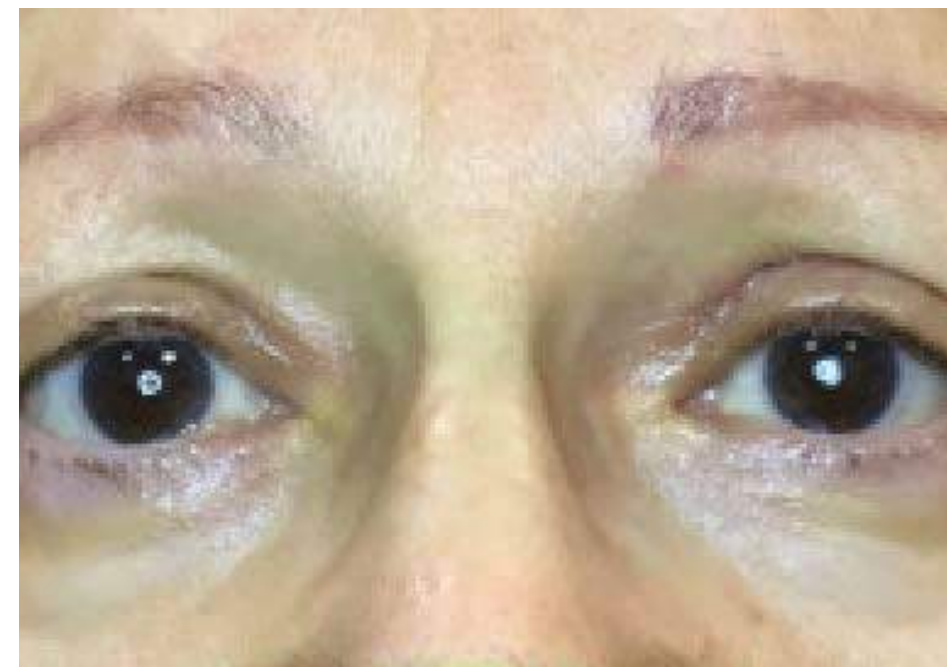
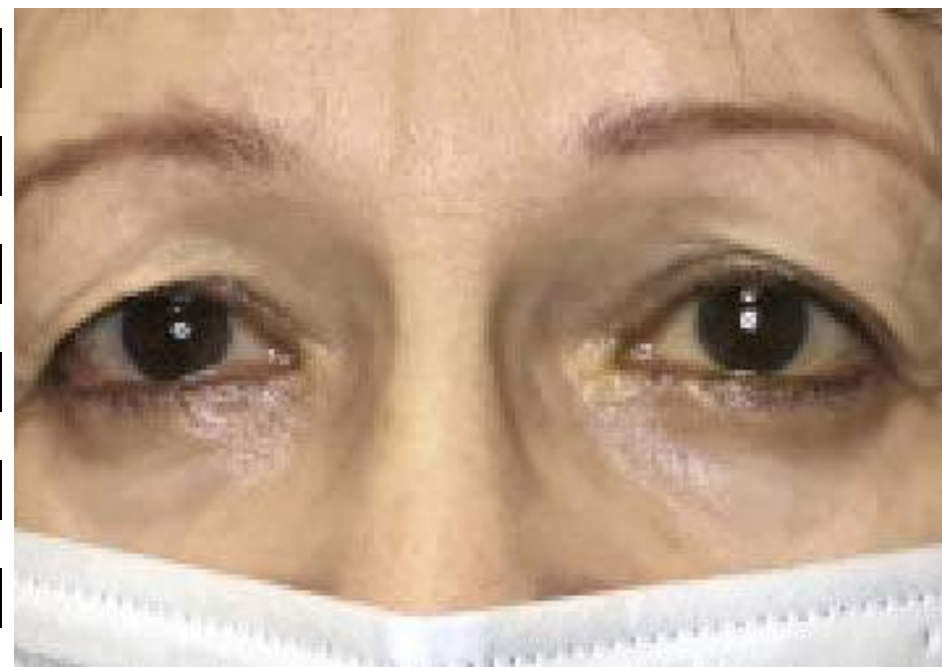Patient Education
Before & After Gallery

Kimberly Cockerham, MD, FACS

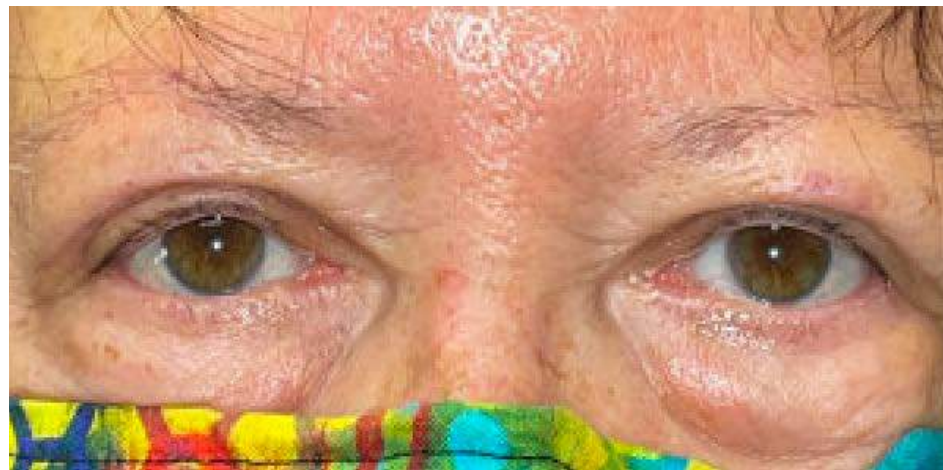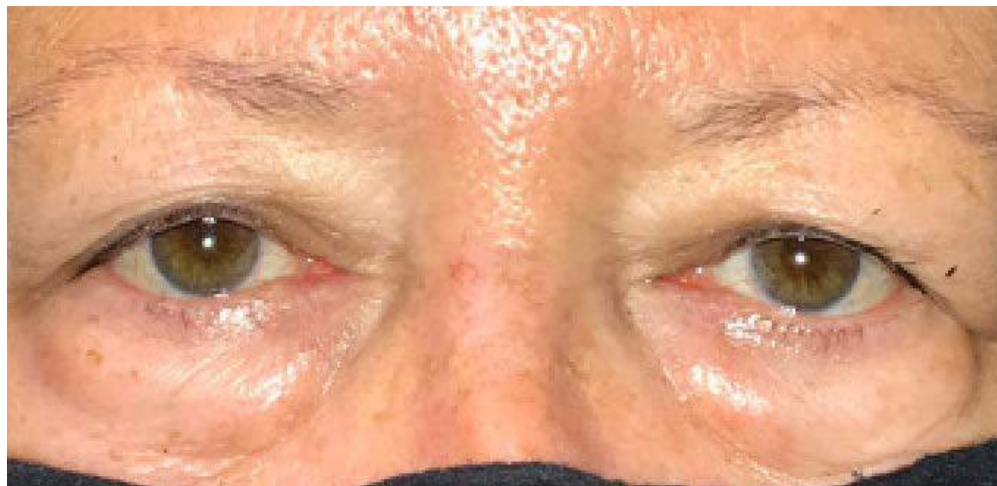Before & After:
Upper Lid Blepharoplasty



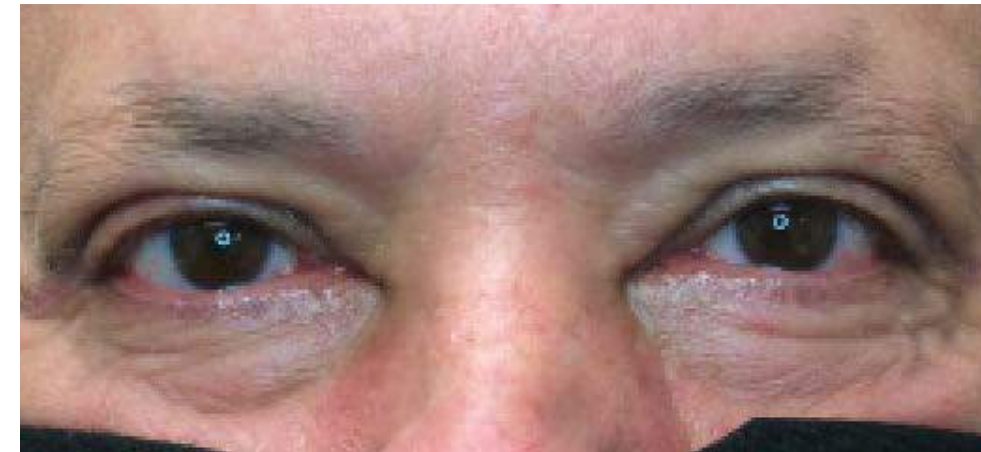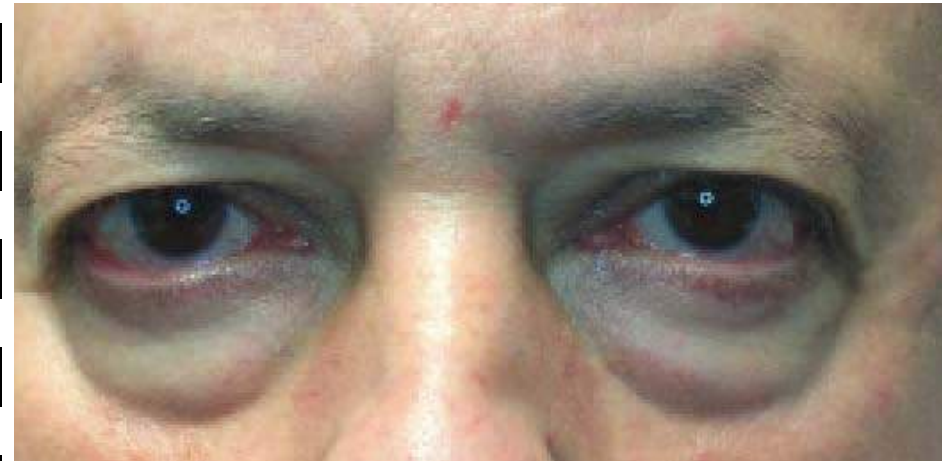Before & After:
Upper Blepharoplasty

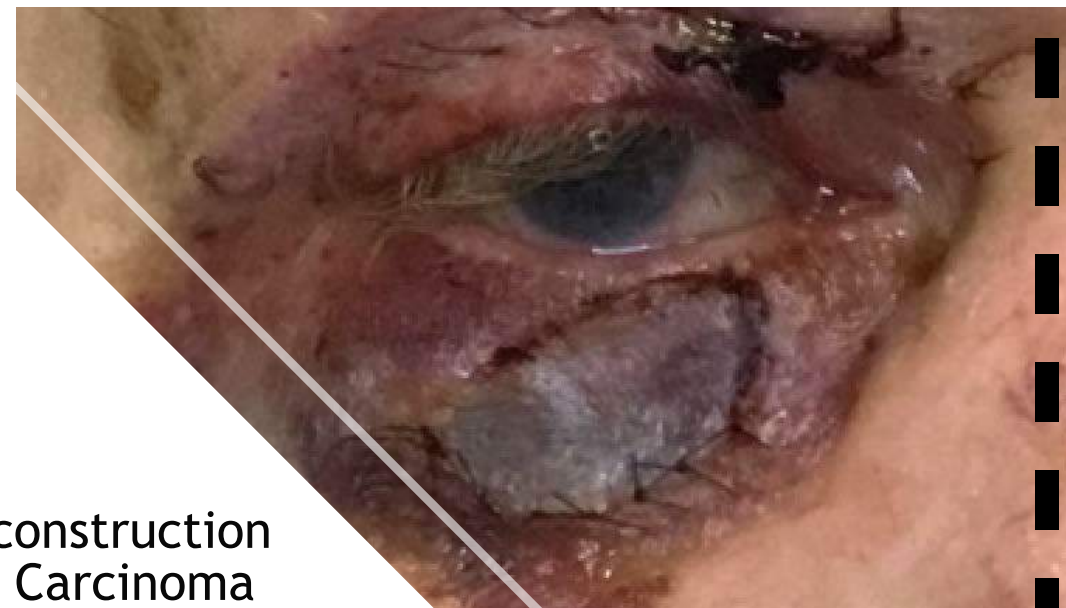
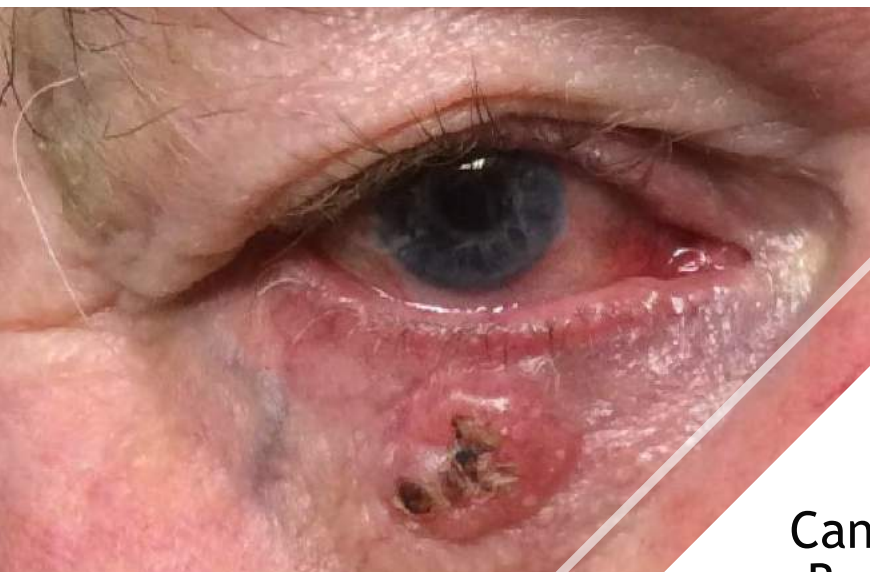
Before & After:
Upper Lid Blepharoplasty

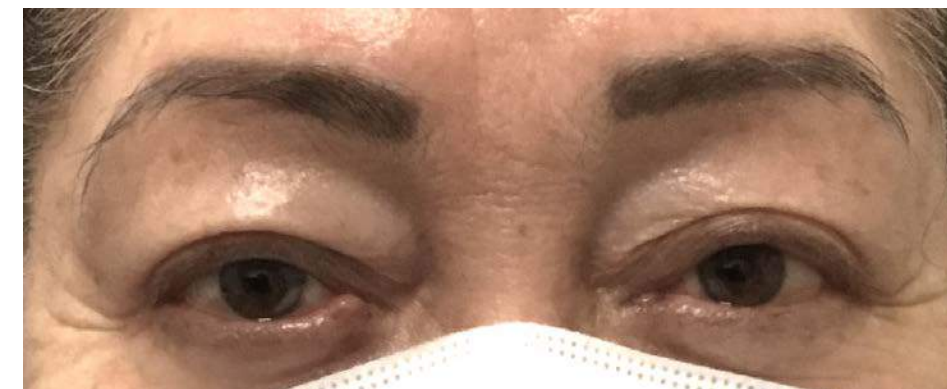
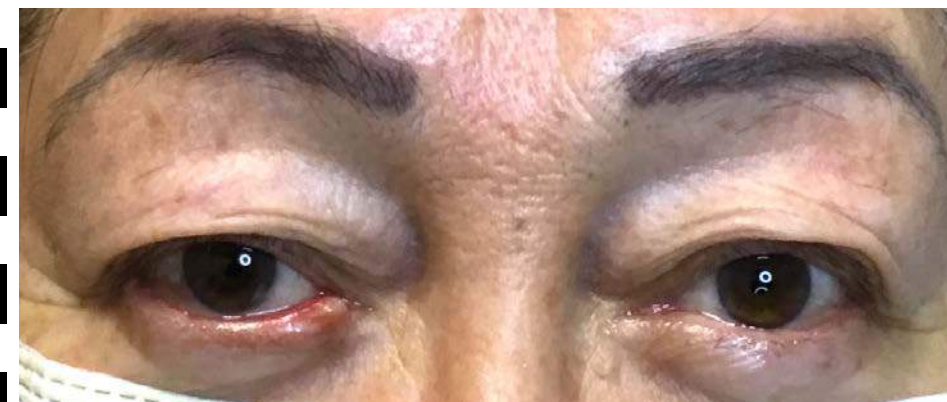
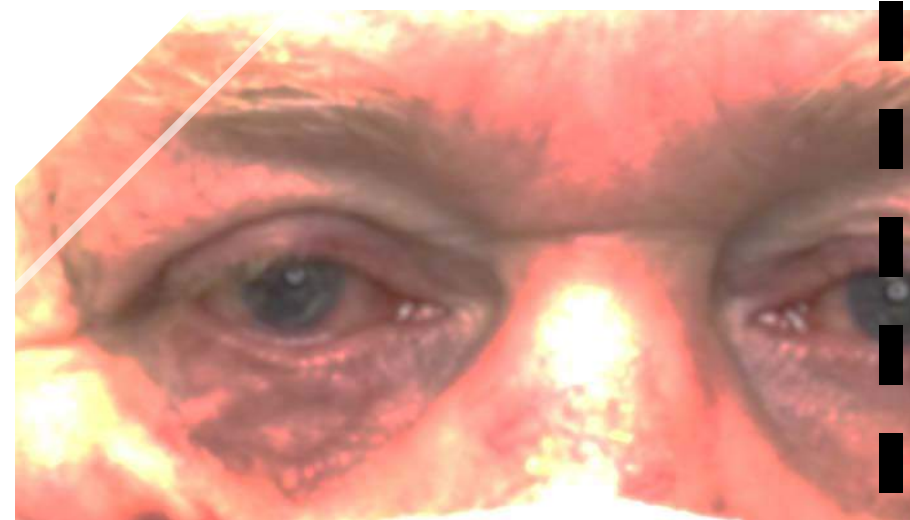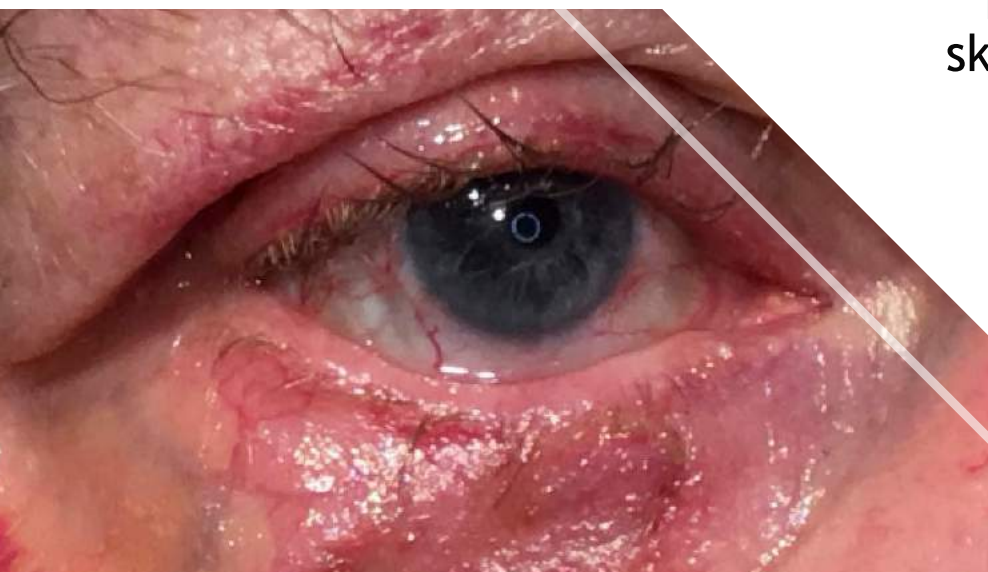Before & After:
Upper Lid Blepharoplasty

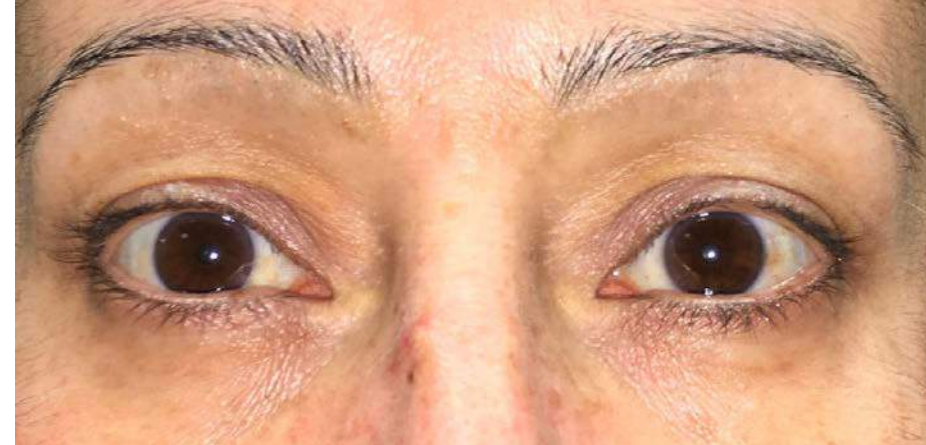
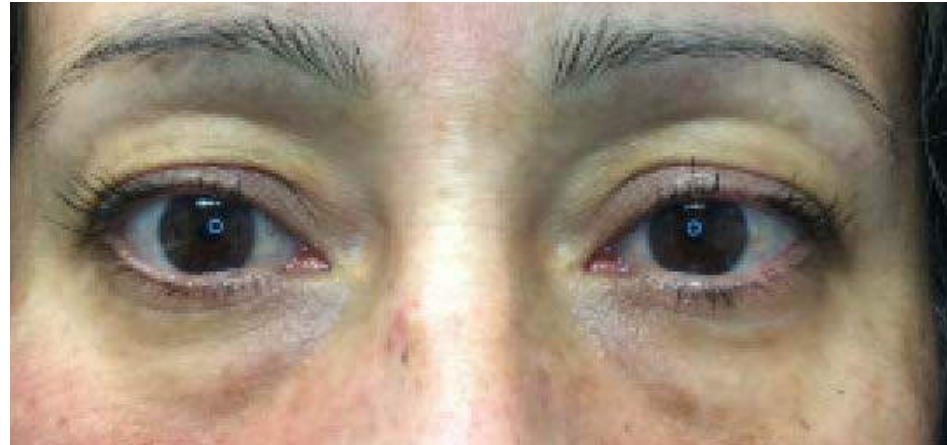




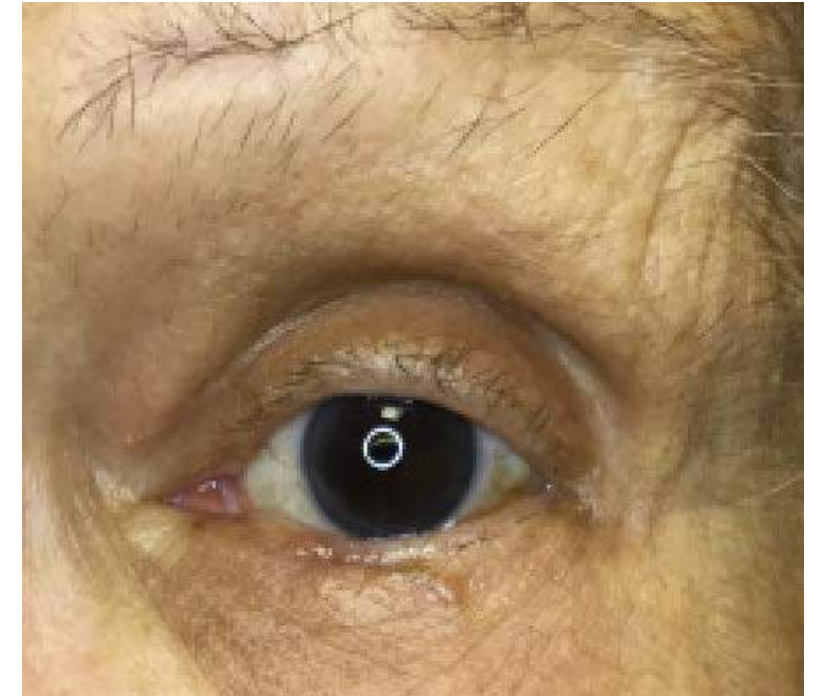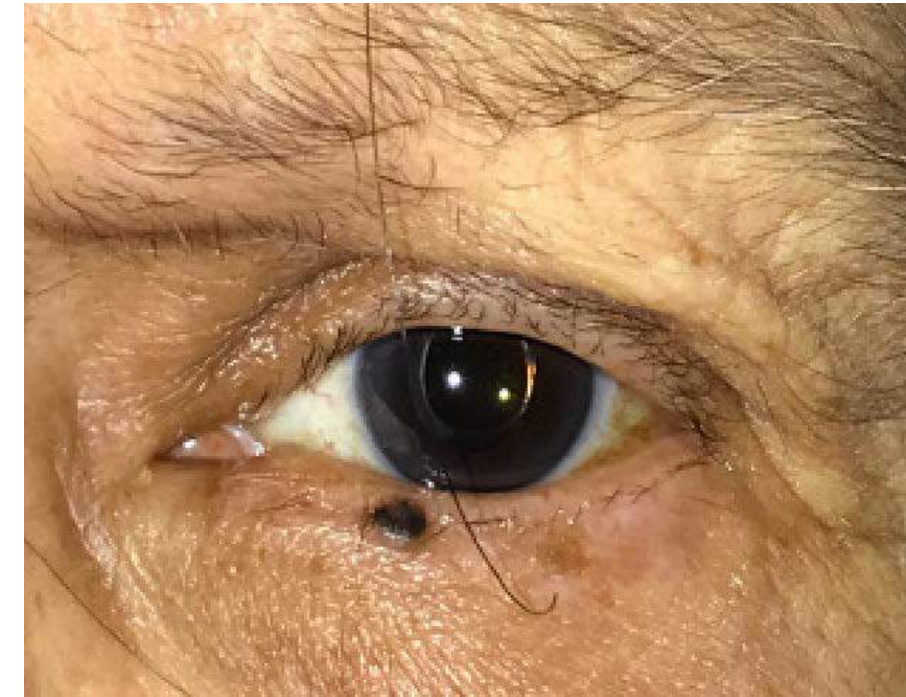
Cancer Reconstruction
Basal Cell Carcinoma
B & A
skin graft



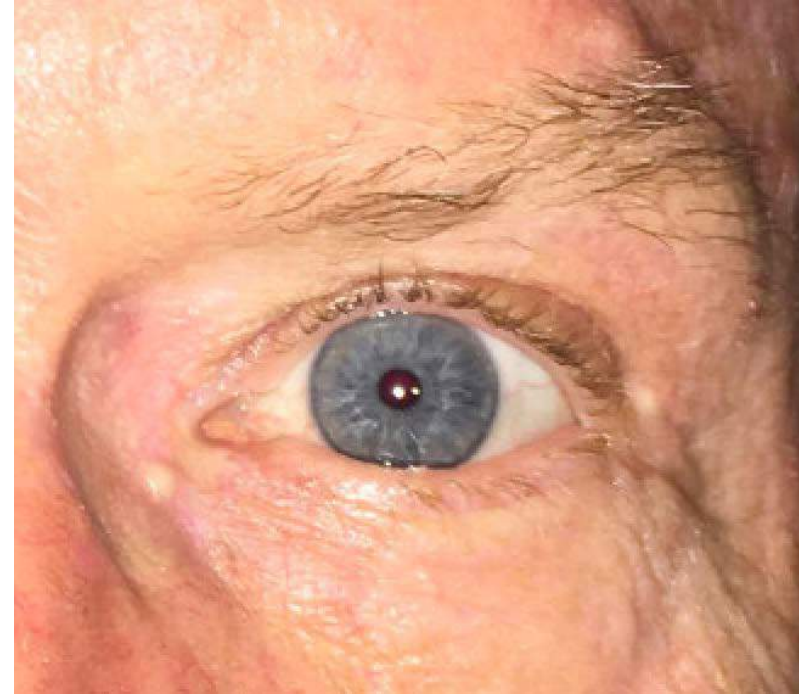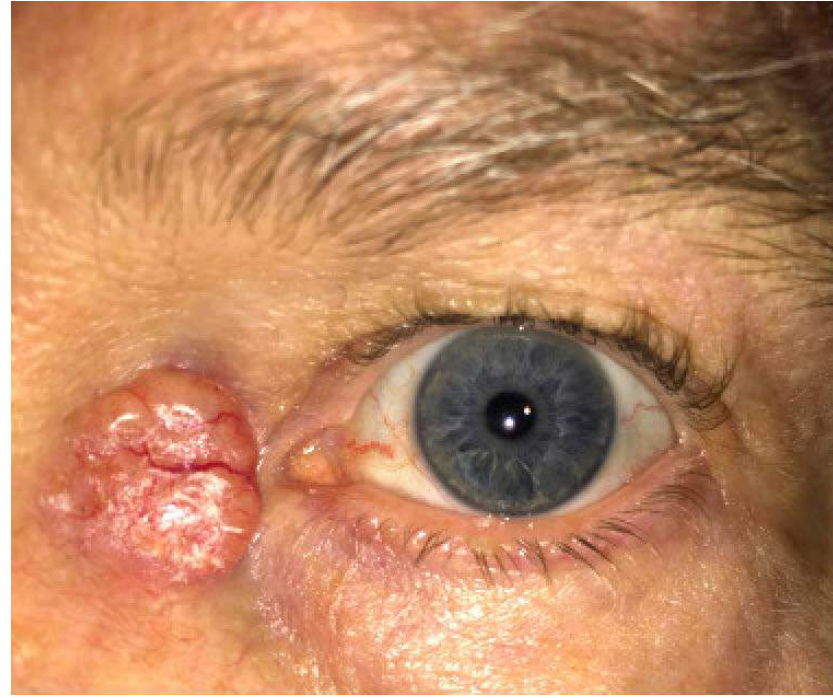Before & After: Upper Lid Blepharoplasty
and Right Lower Lid Ectropion



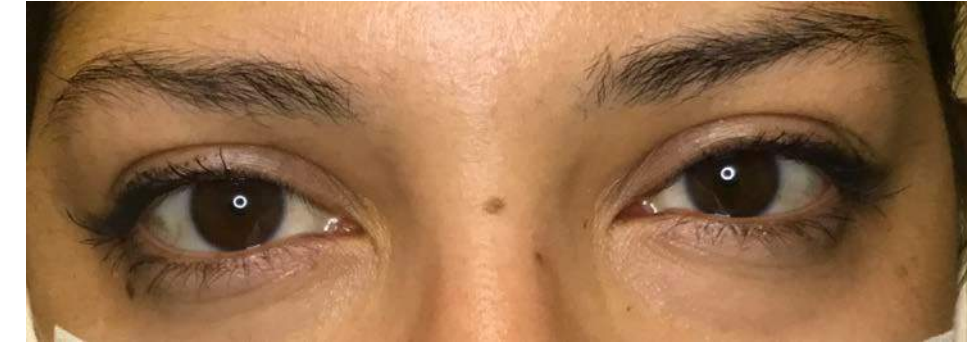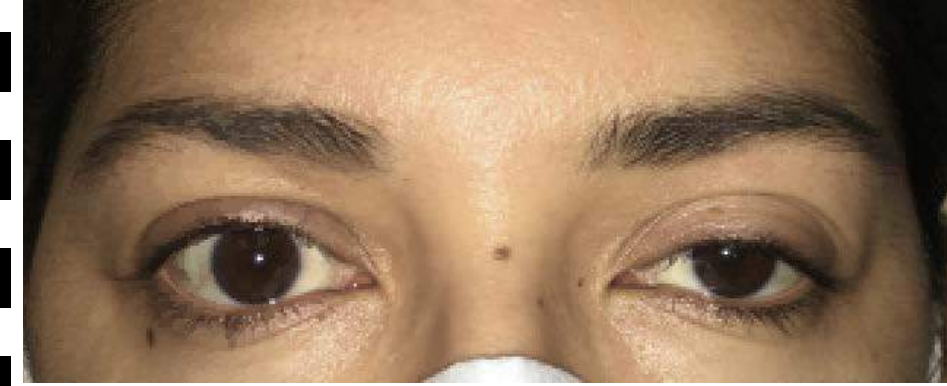Before & After: Transconjunctival Lower Lid
Blepharoplasty (Cosmetic Self Pay)



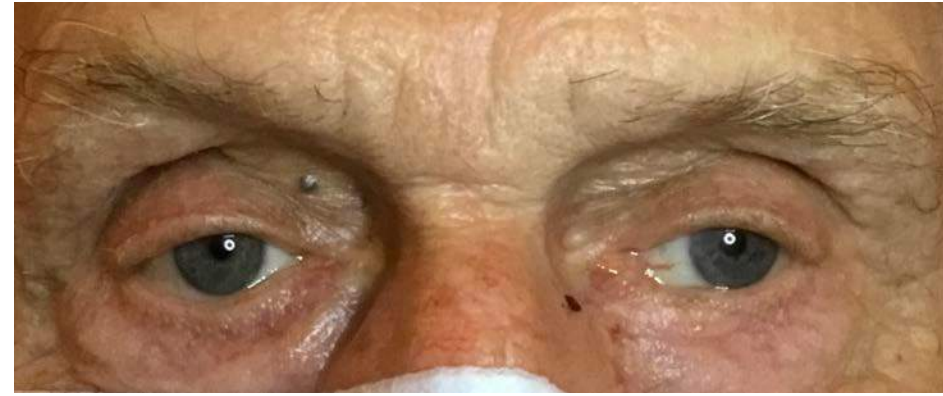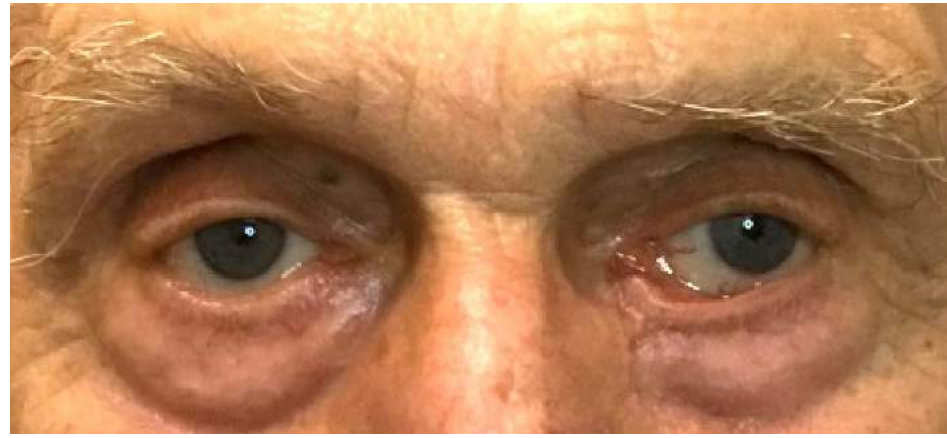
Before & After: Excisional Biopsy Left Lower
Eyelid Melanoma with Flap Reconstruction



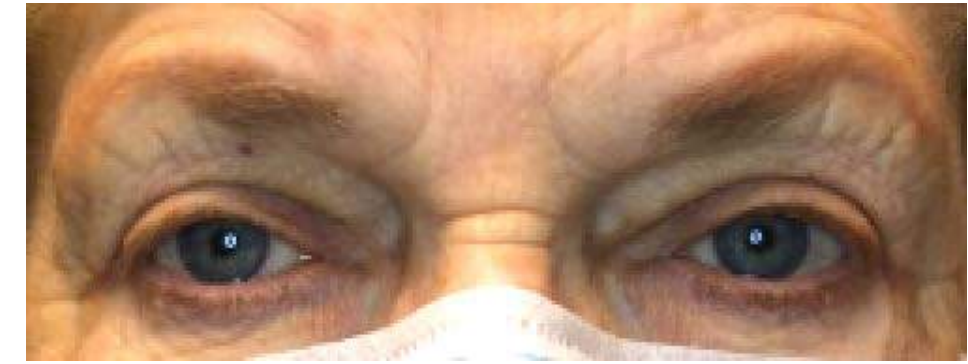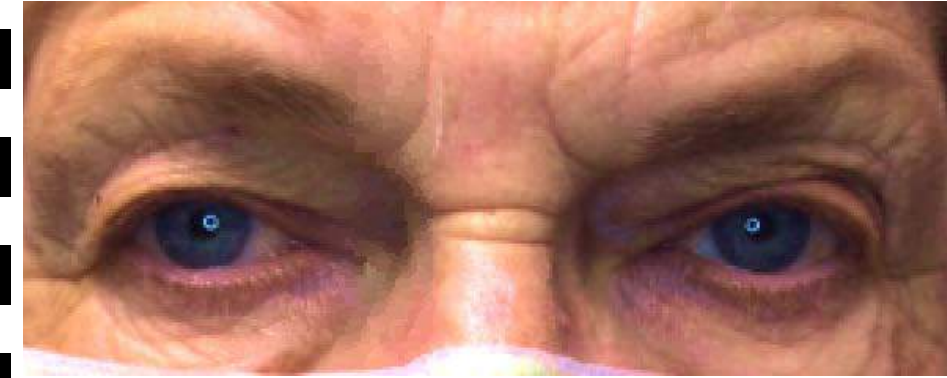Before & After: Basal Cell Cancer
Excision and Flap Reconstruction



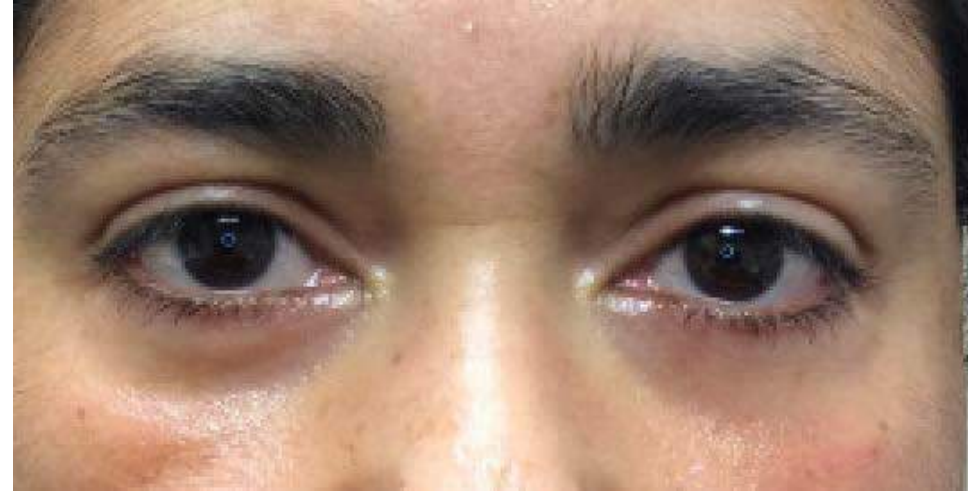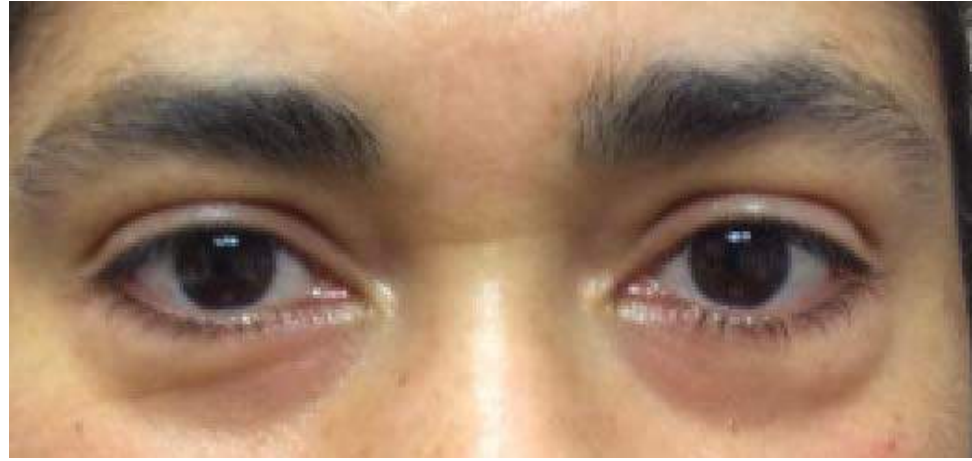Before & After:
Left Internal Ptosis Repair



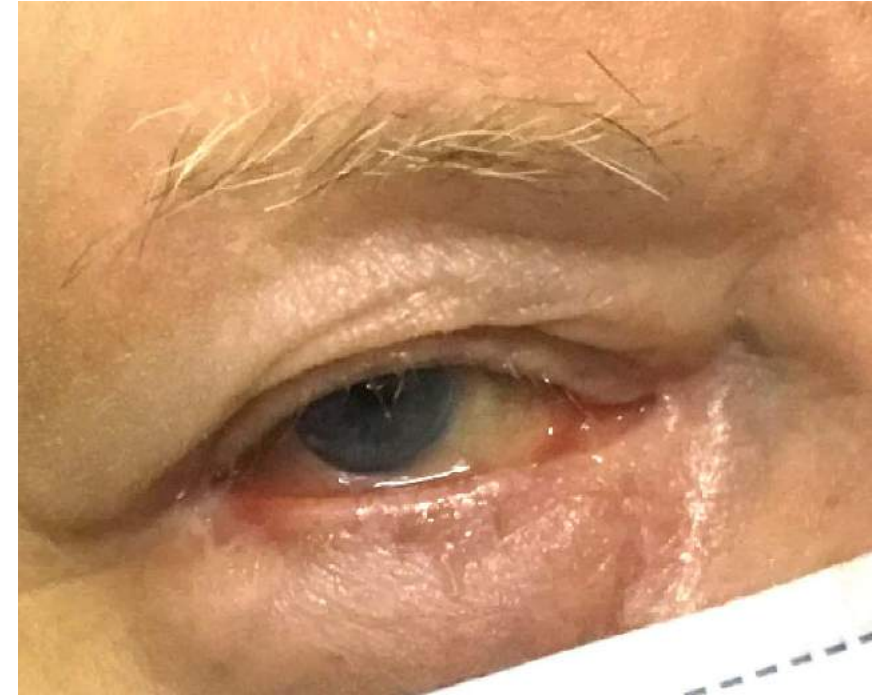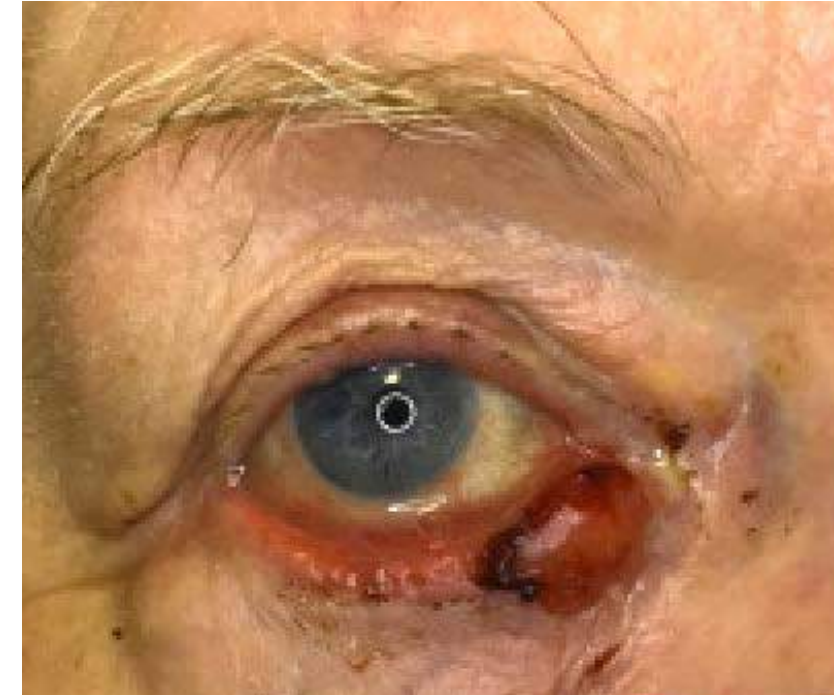Before & After: Left Lower Eyelid Ectropion
and Eyelid Retraction Repair



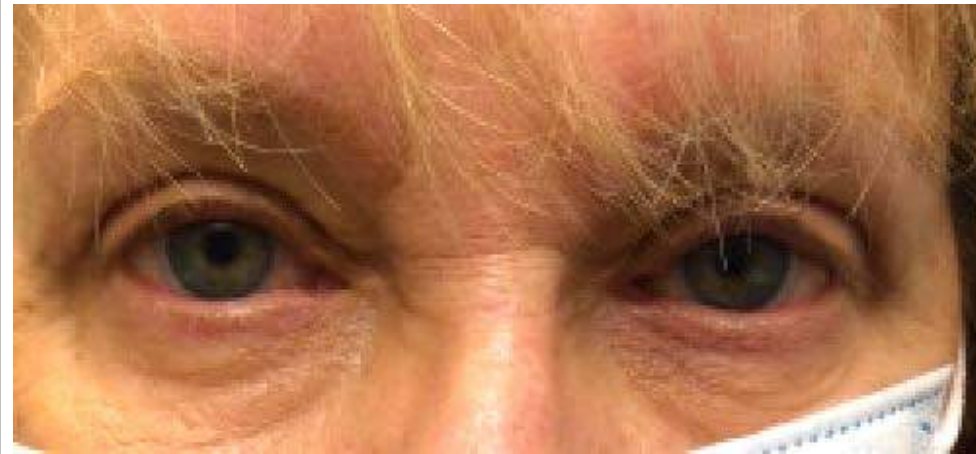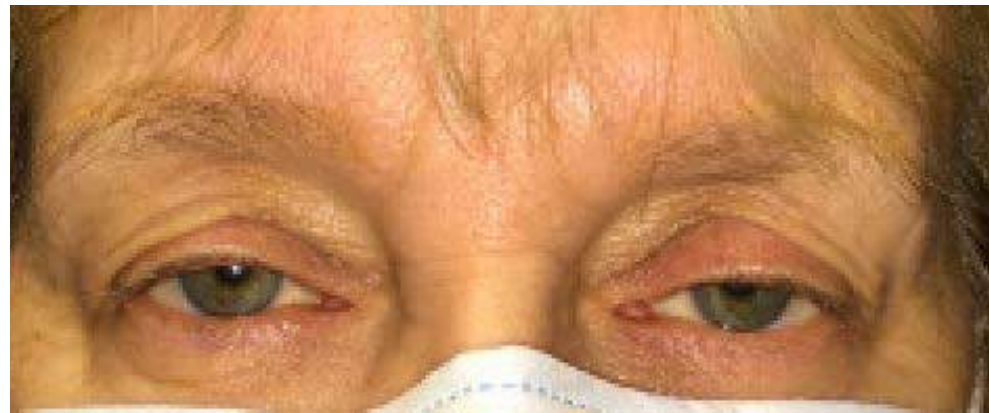Before & After:
Upper Lid Blepharoplasty



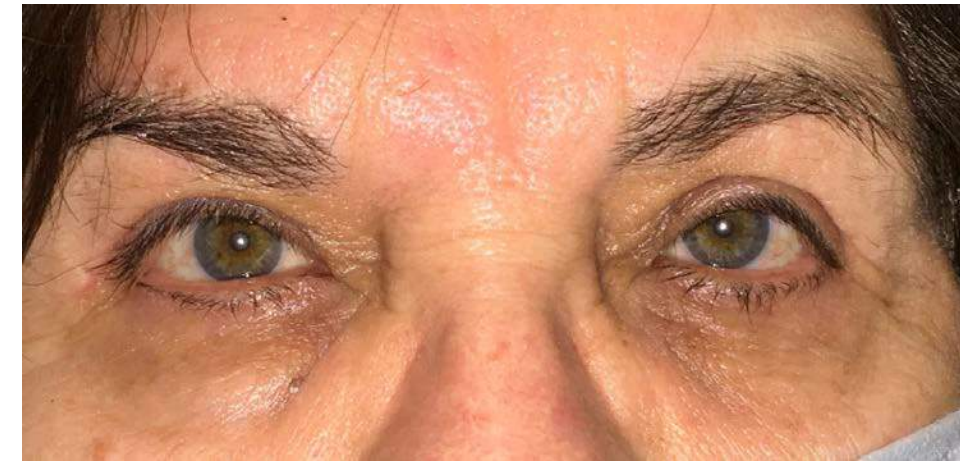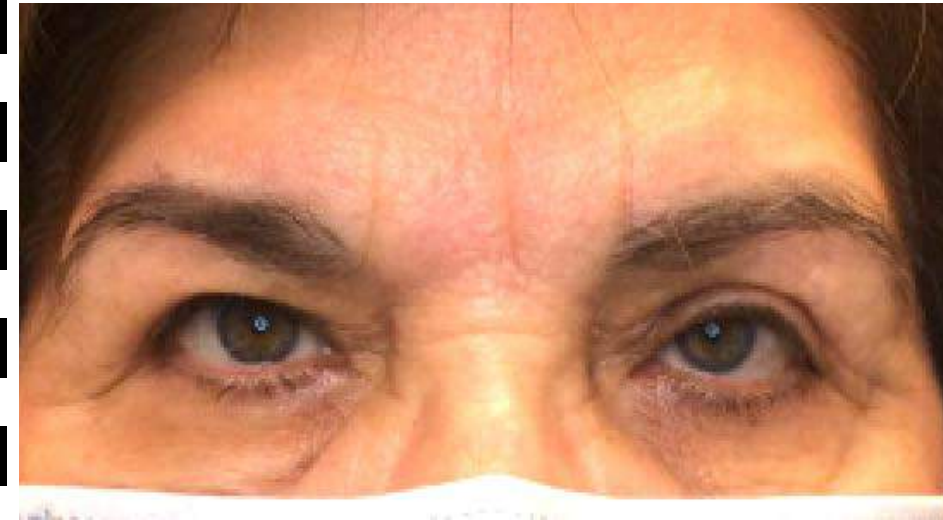Before & After: Lower Lid Transconjunctival
Blepharoplasty (cosmetic self pay)



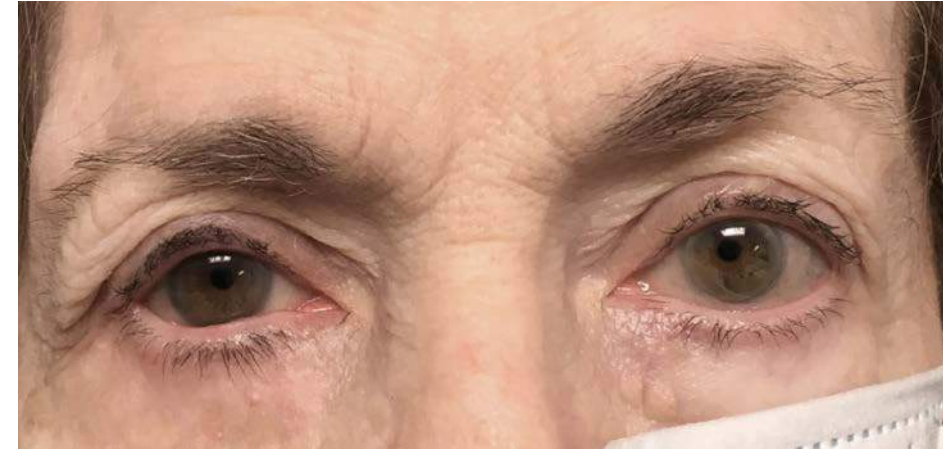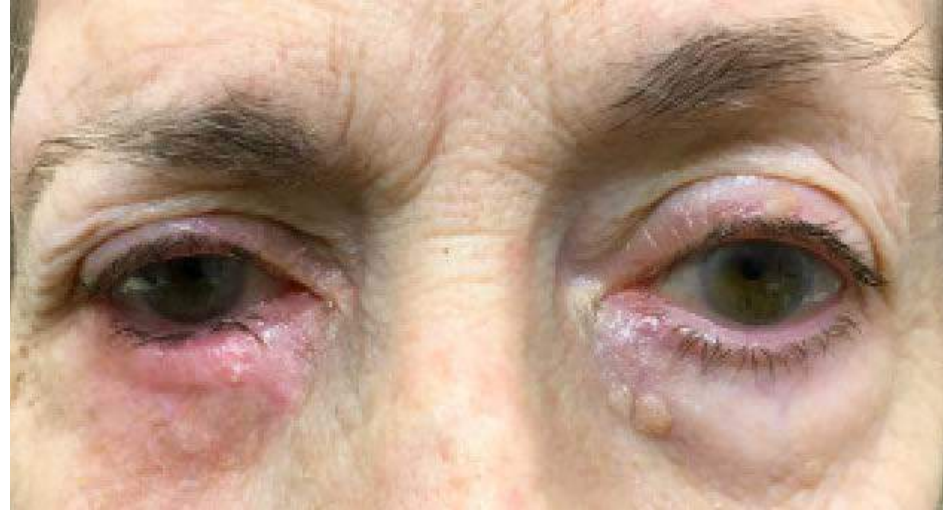Before & After: Eyelid Cancer Resection
and Reconstruction of Lower Lid
(myasthenia gravis » upper eyelid drooping)



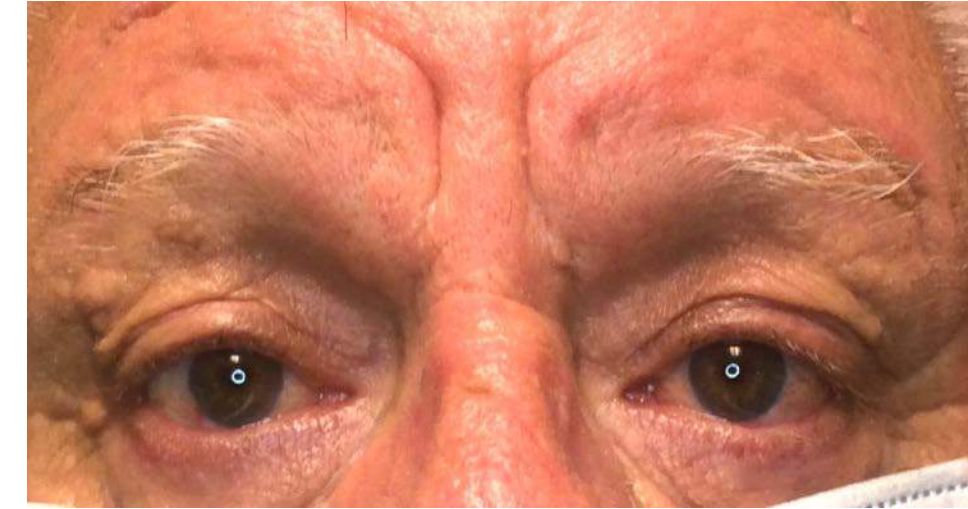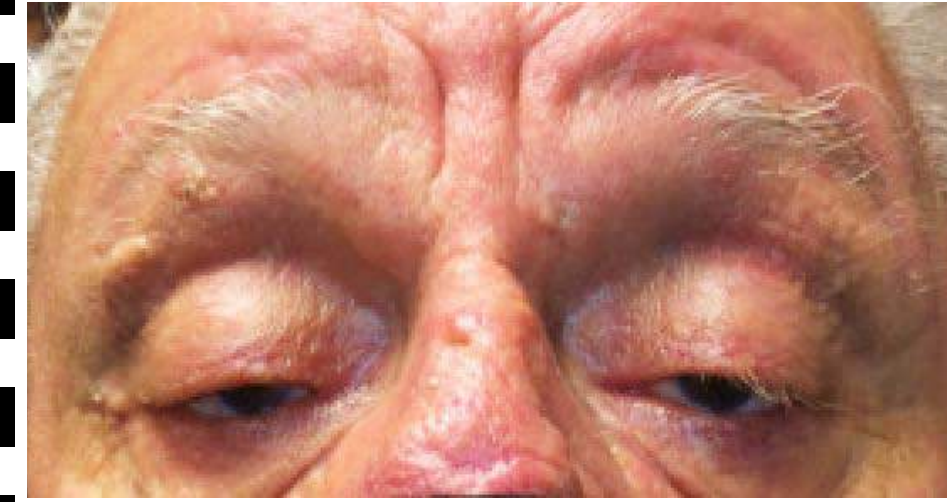Before & After: Internal Ptosis Repair and
Blepharoplasty Upper Eyelid Skin Removal
and Muscle Tightening



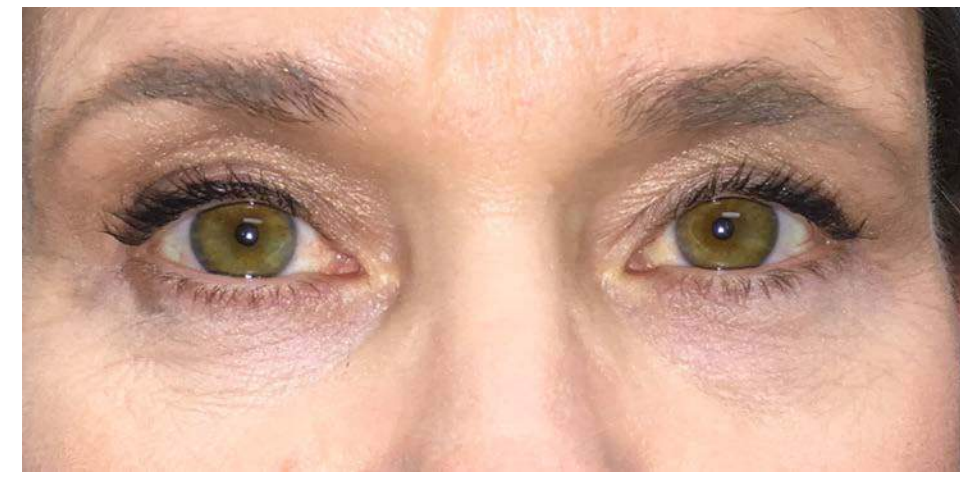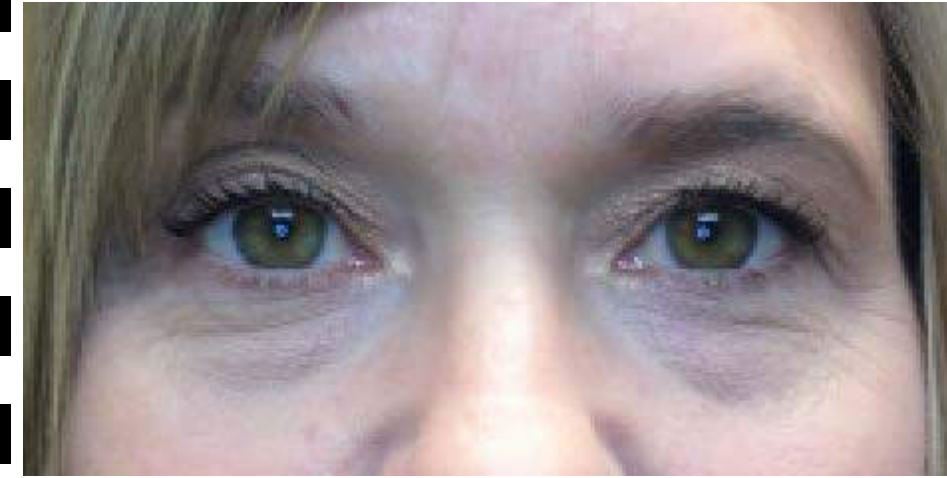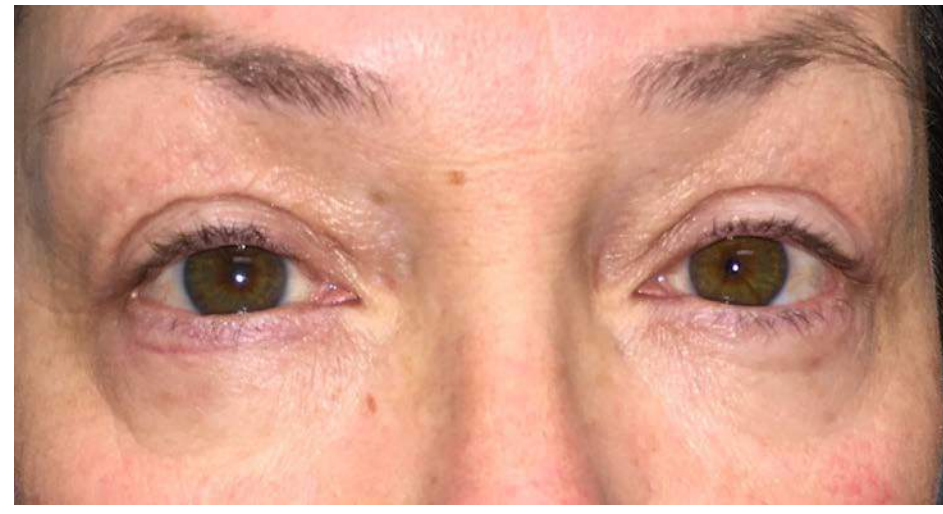
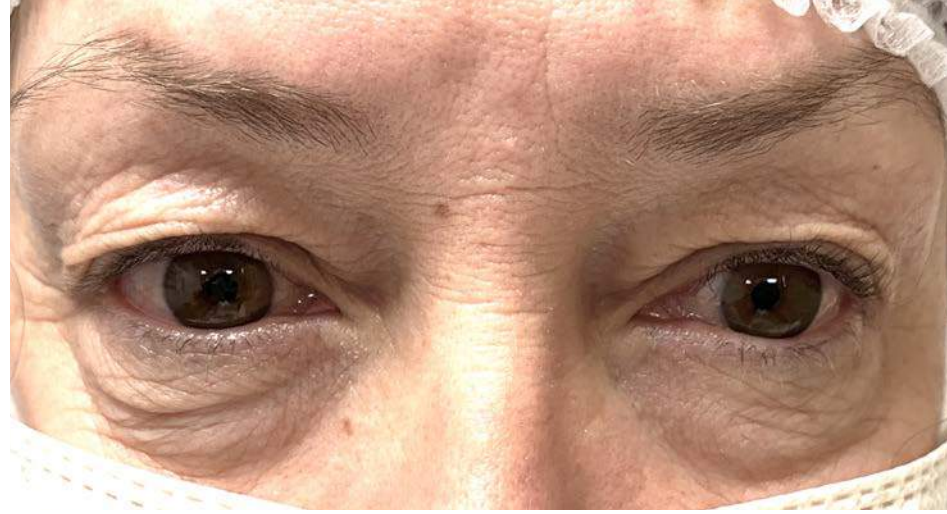Before & After: Right Upper Eyelid
Blepharoplasty (upper eyelid skin removal)



Before & After: Right Lower Eyelid Entropion
Repair (correction of in-turning eyelids)

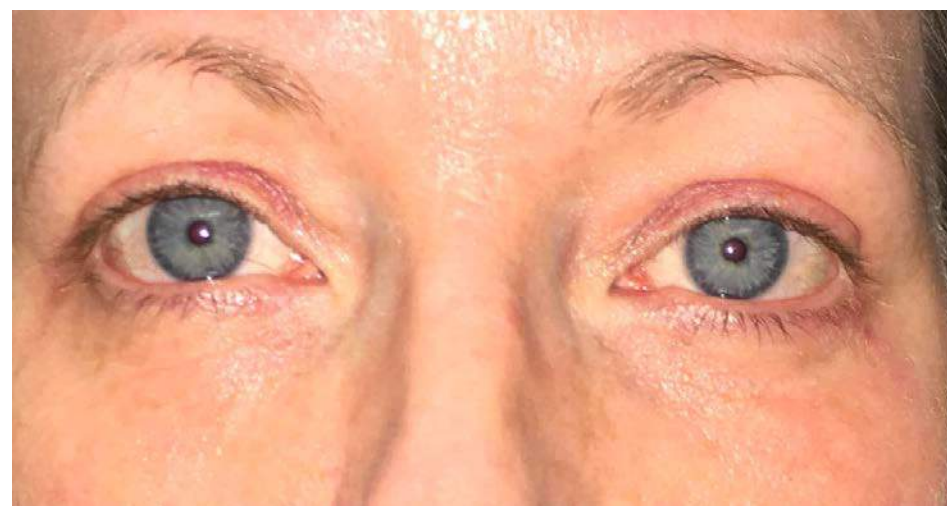
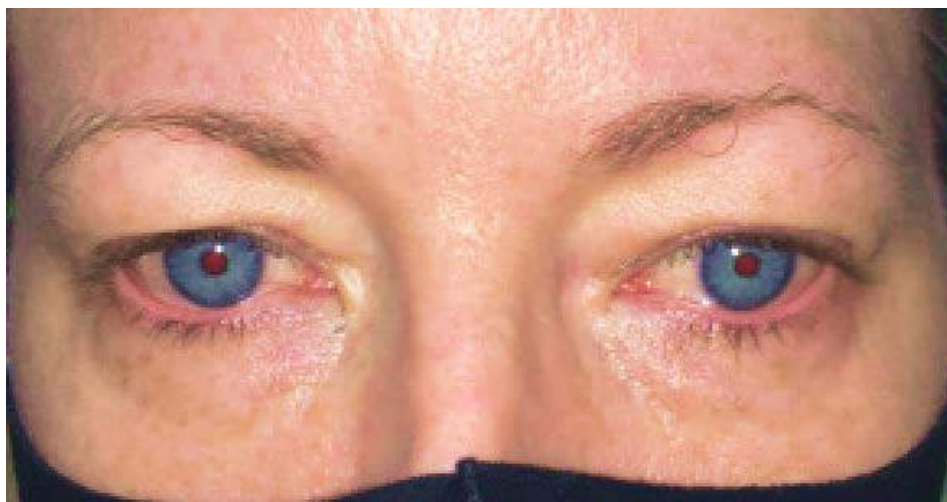

Before & After: Bilateral Eyelid Ptosis Repair
(Internal Ptosis and Frontalis Sling) for
Chronic Progressive Ophthalmoplegia (CPEO)

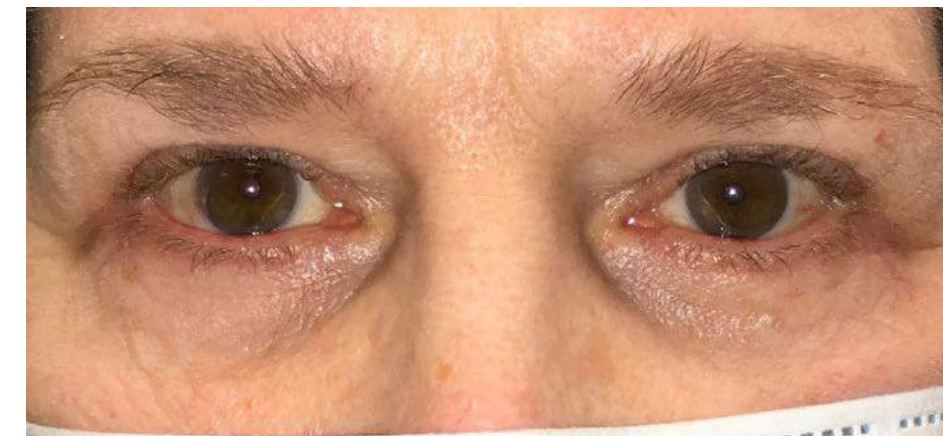
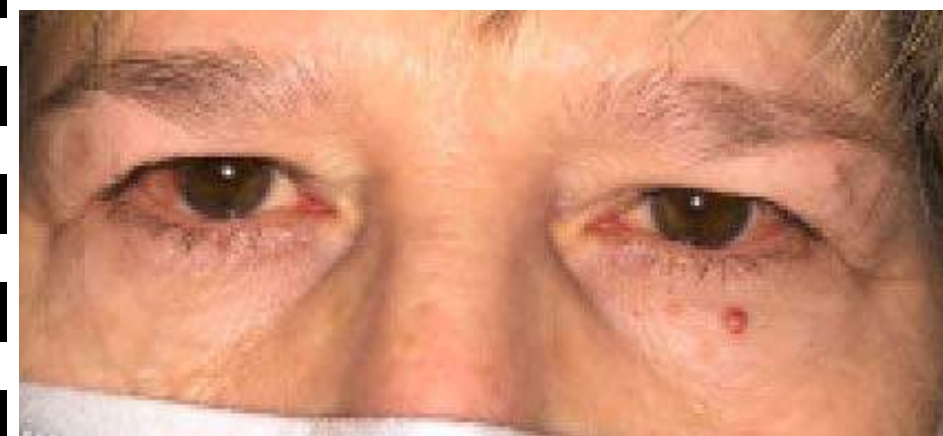

Before & After: Two weeks following
Bilateral Upper and Lower Lid
Blepharoplasty (cosmetic self pay)

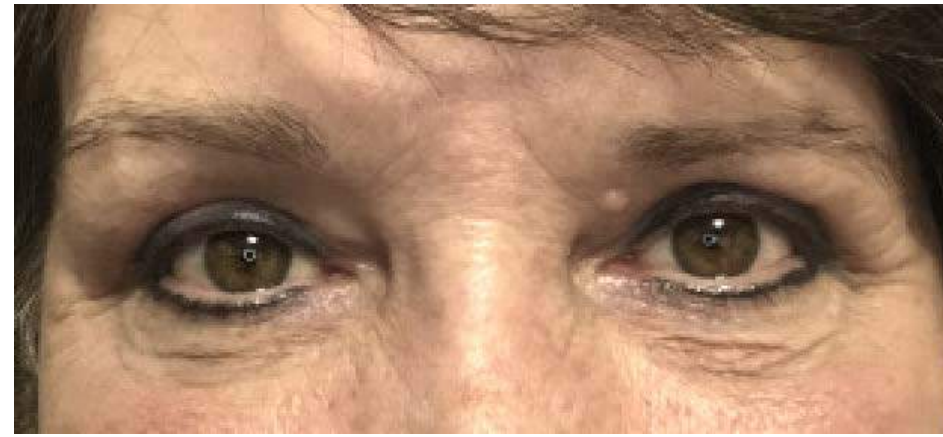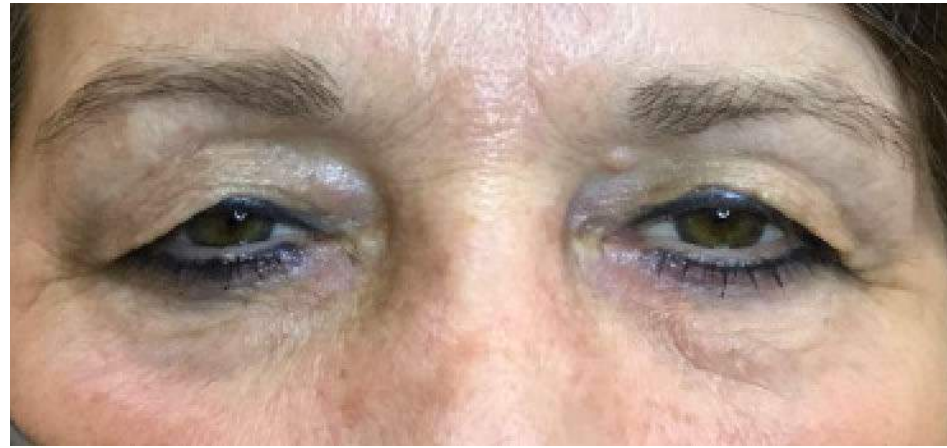Before & After: Bilateral Upper and Lower
Lid Blepharoplasty (cosmetic self pay)



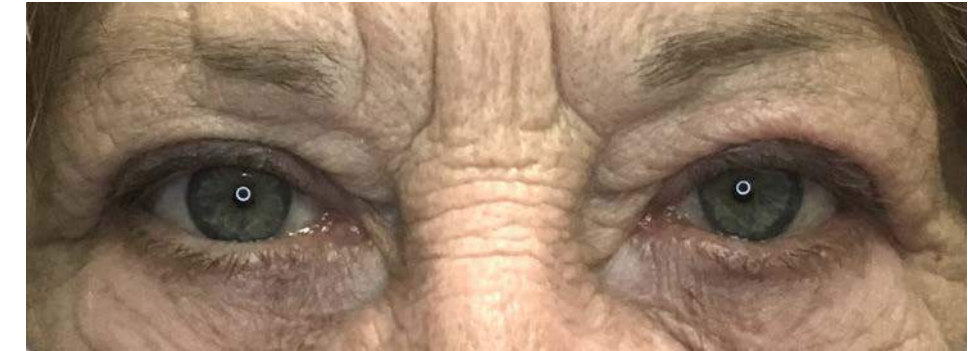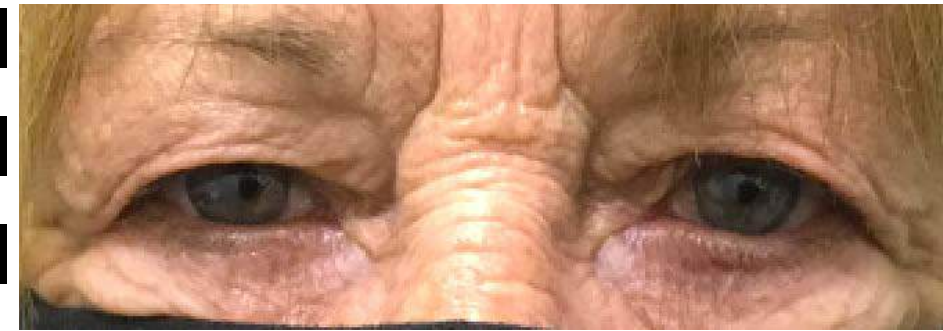Before & Two Weeks After:
Bilateral Upper Lid Blepharoplasty



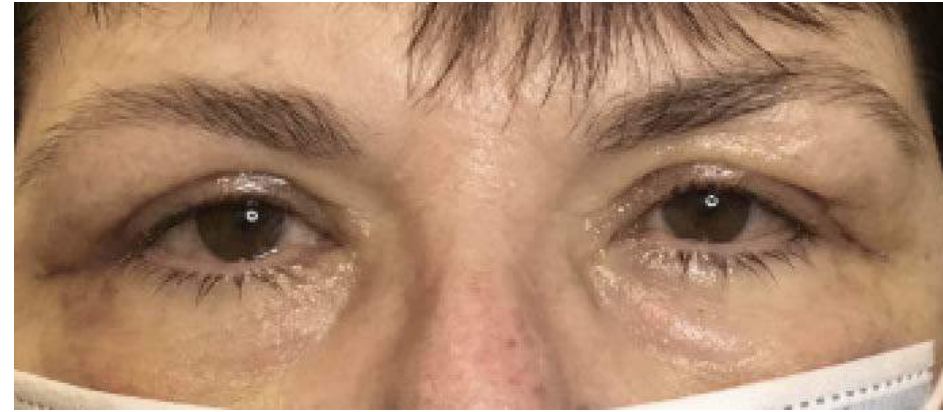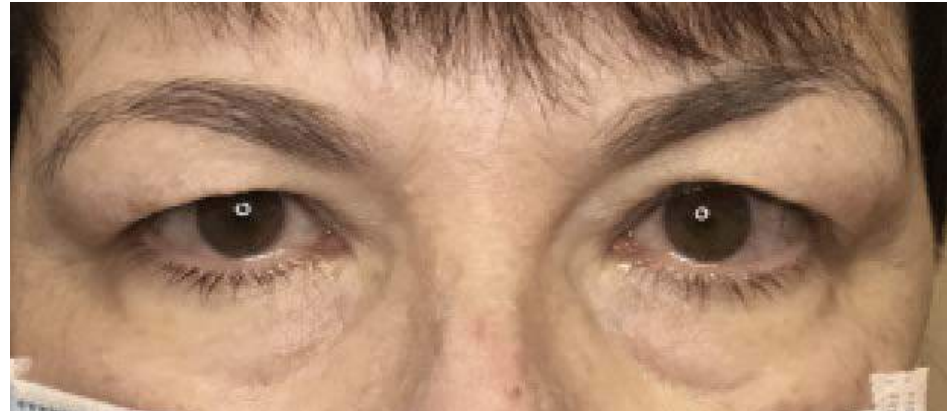Before & After: Bilateral Upper Lid
Blepharoplasty and Brow Lift



Before & After: Bilateral Upper Lid
Blepharoplasty and Brow Lift

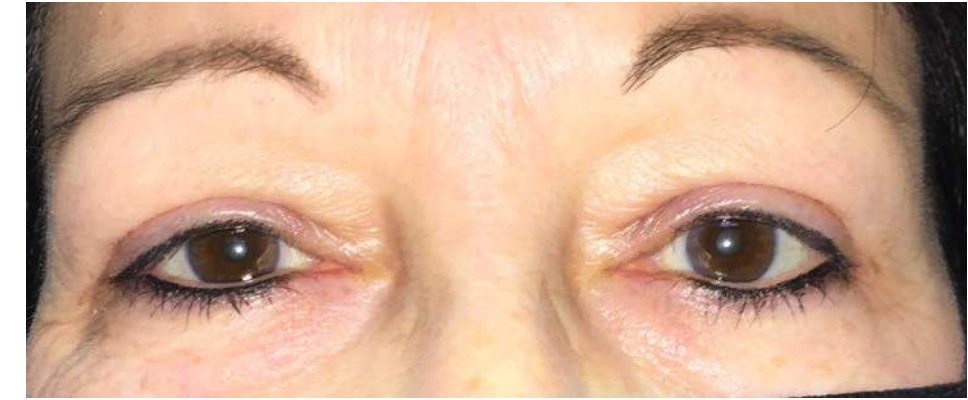
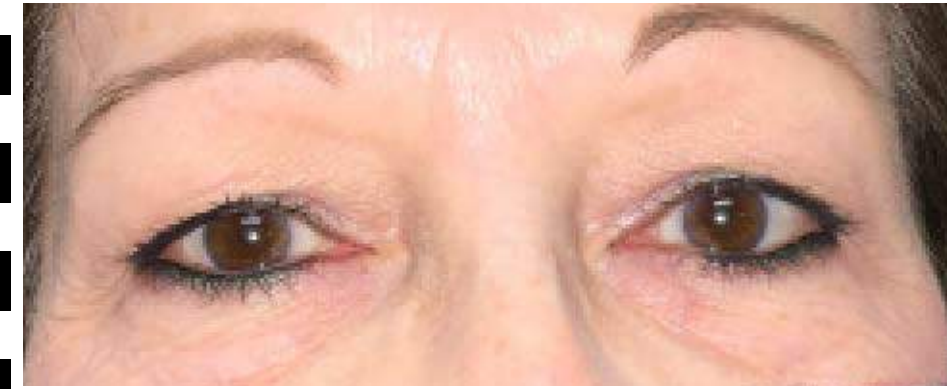
Before & After:
Bilateral Upper Lid Blepharoplasty



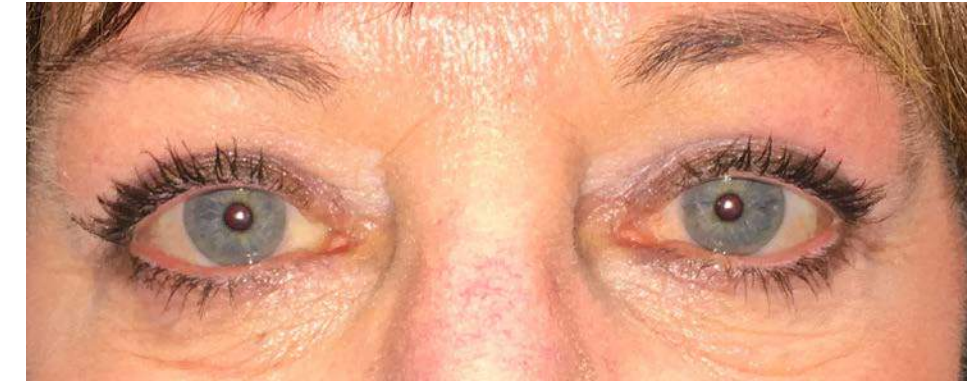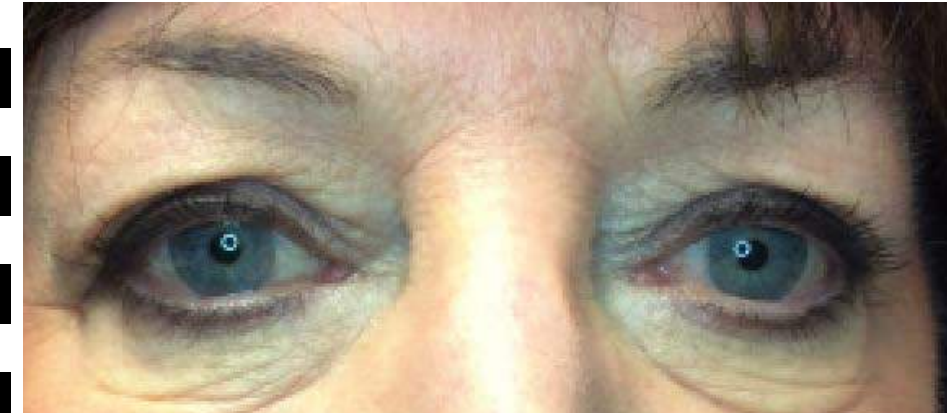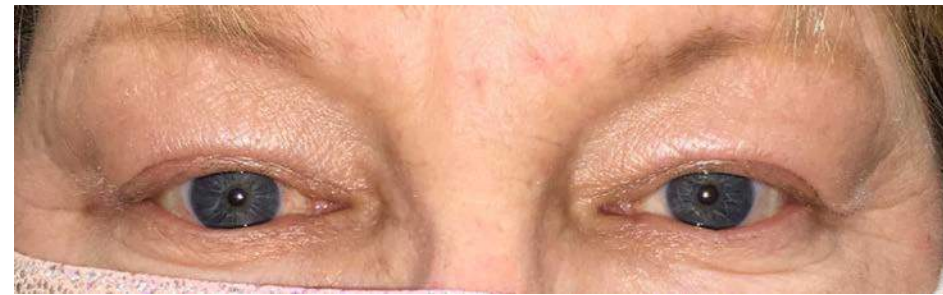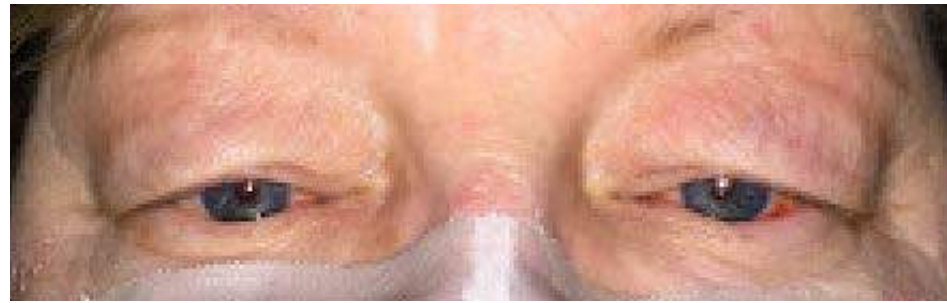Before & After: Post-Op Day 7

Bilateral Upper Lid Blepharoplasty



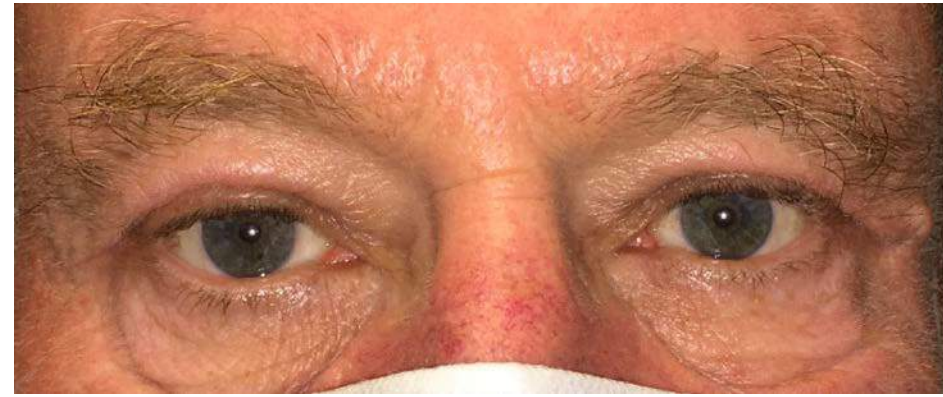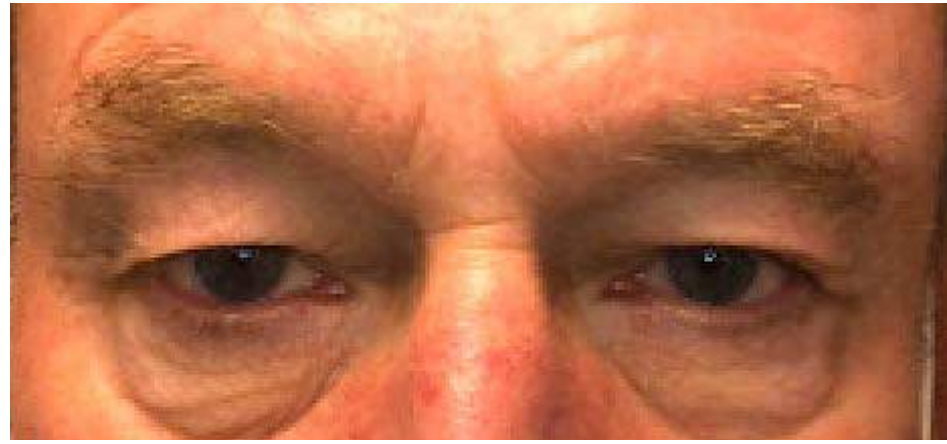Before & After: Post-Op Day 7

Bilateral Upper Lid Blepharoplasty

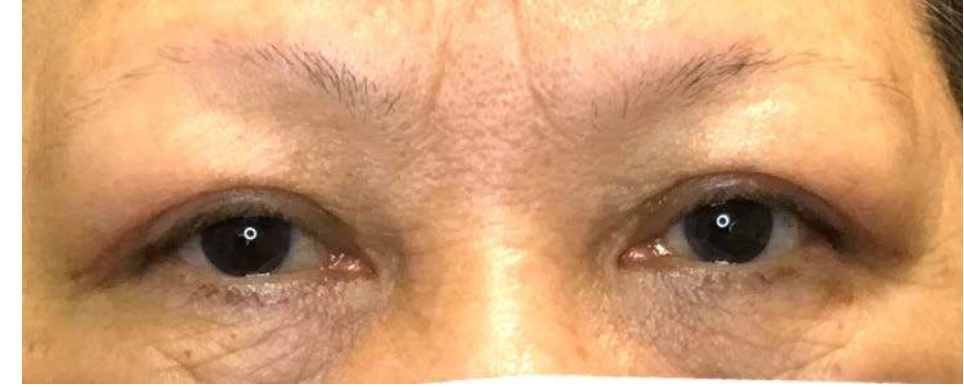
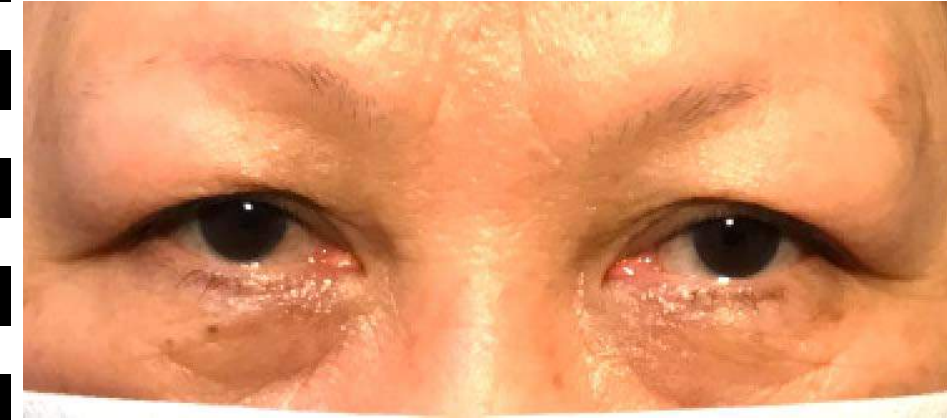
Before & One Month After:
Bilateral Upper Lid Blepharoplasty

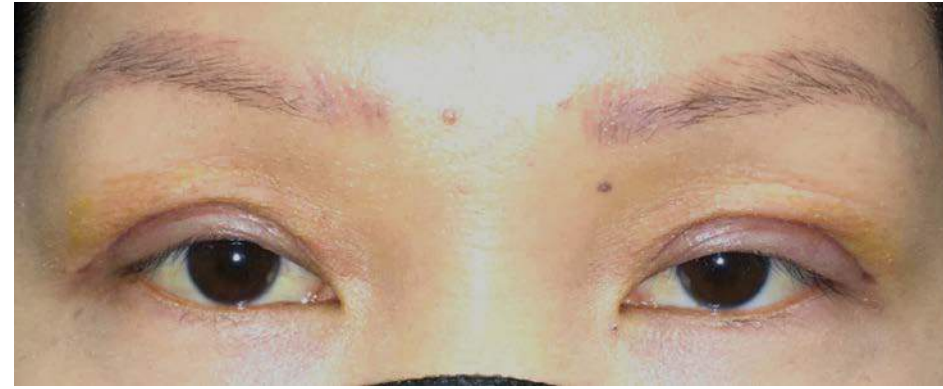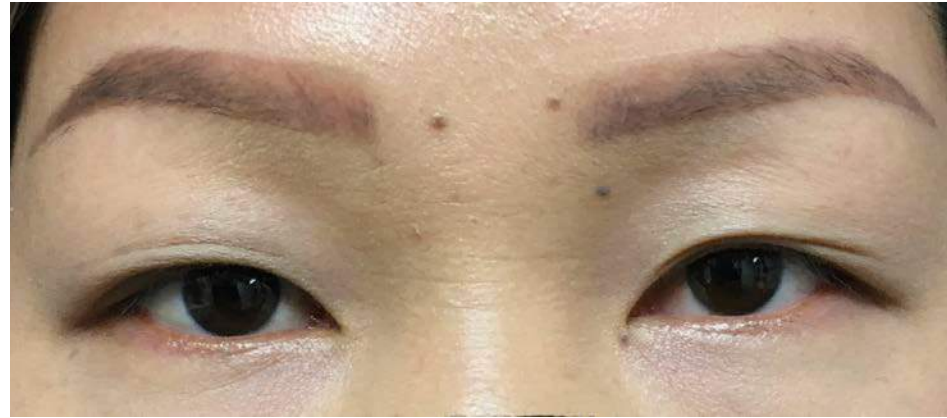Before & Three Months After:
Upper Lid Blepharoplasty and Resurfacing
of Lower Eyelids



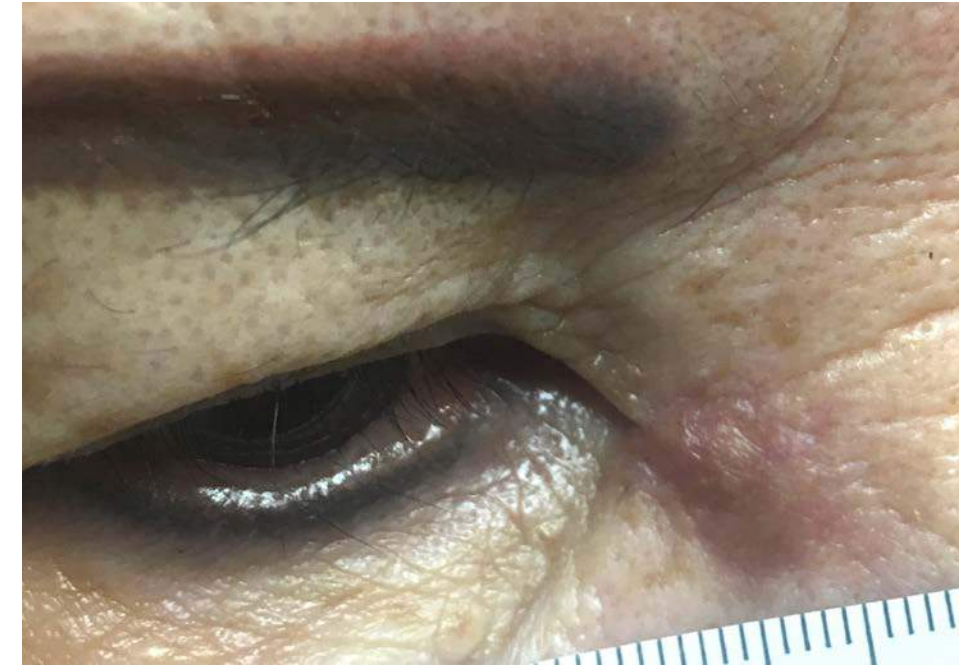
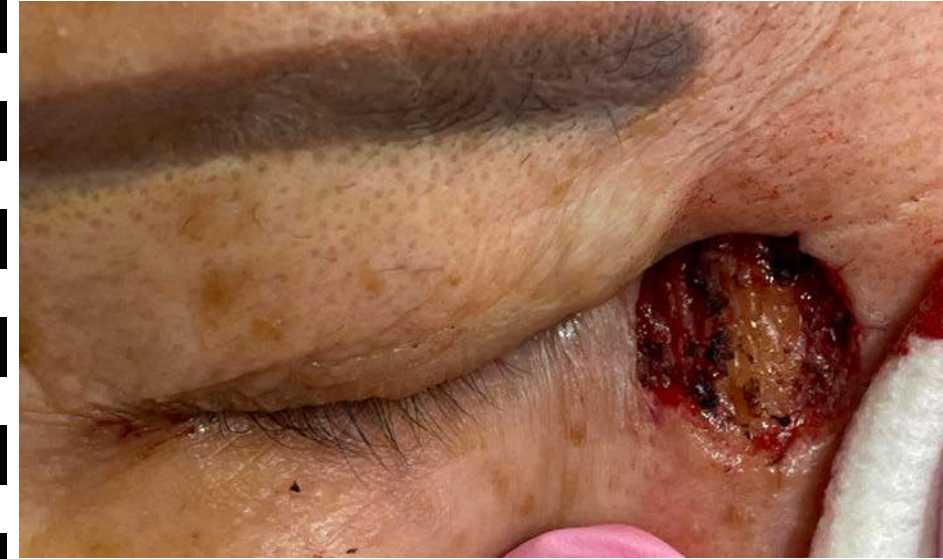Before & One Month After:
Bilateral Upper Lid Blepharoplasty



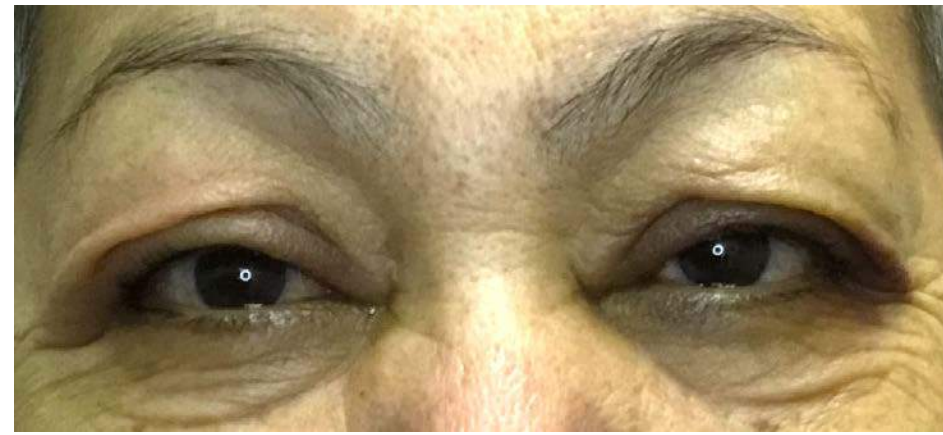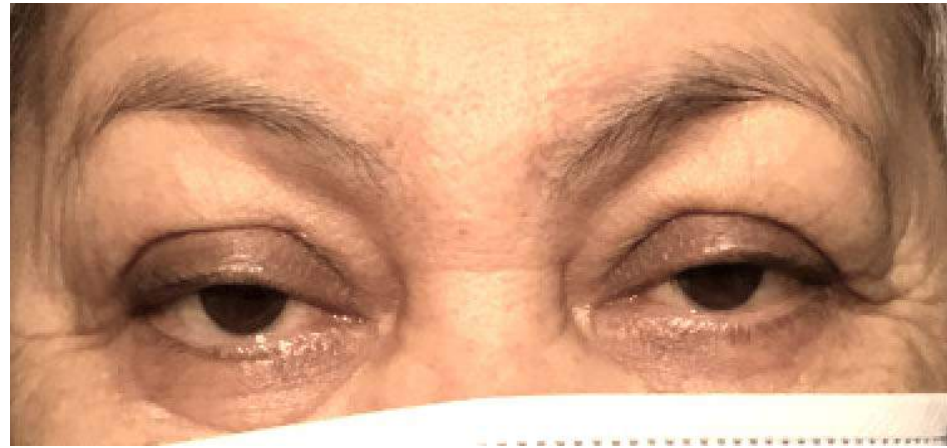Before & One Month After:
Upper Lid Blepharoplasty



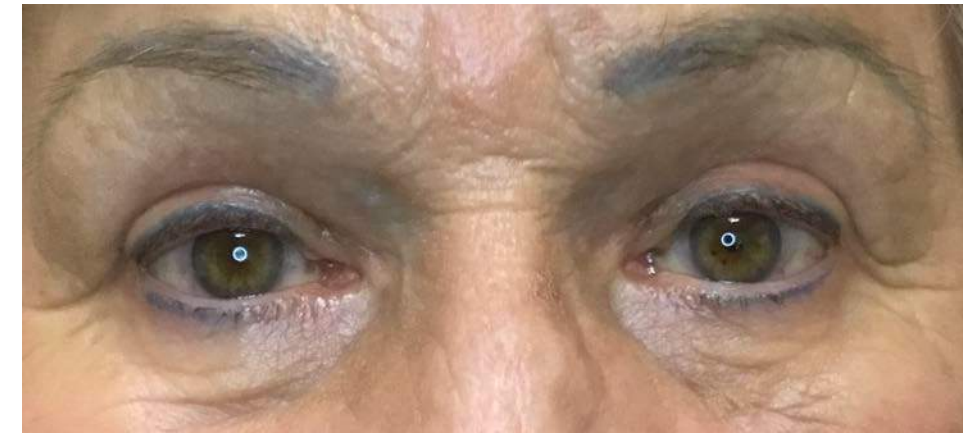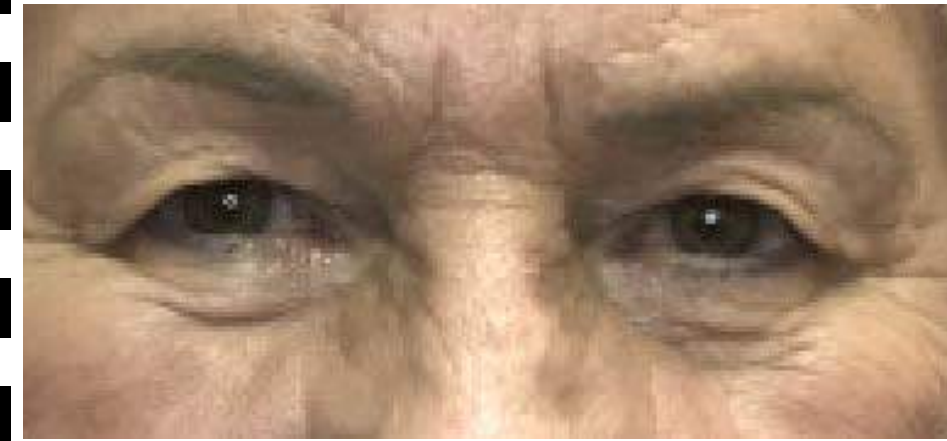Before & One Week After:
Double Eyelid Surgery



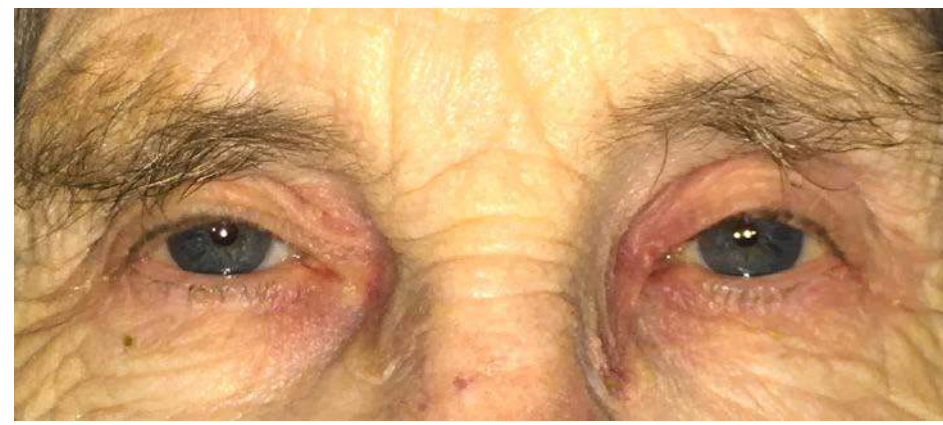
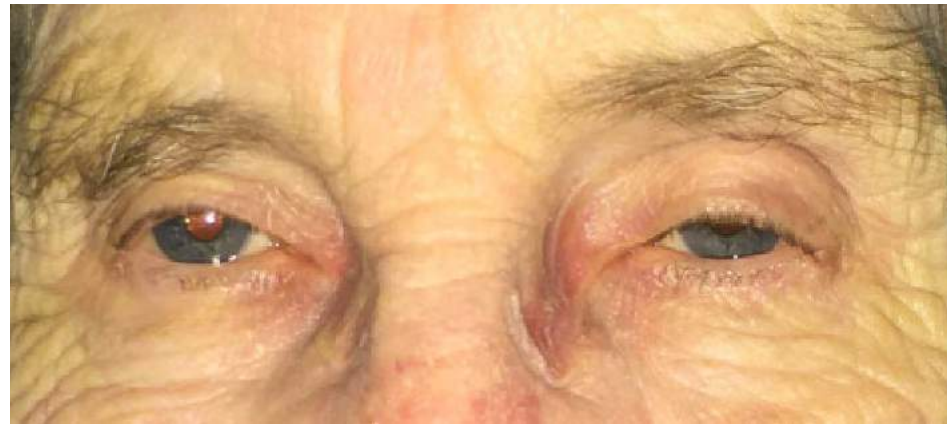Before & One Month After:
Post-MOHS Reconstruction for Skin Cancer



Before & One Month After: Bilateral Internal
Ptosis Repair for Weakened Eyelid Muscle
(No Skin Removal)

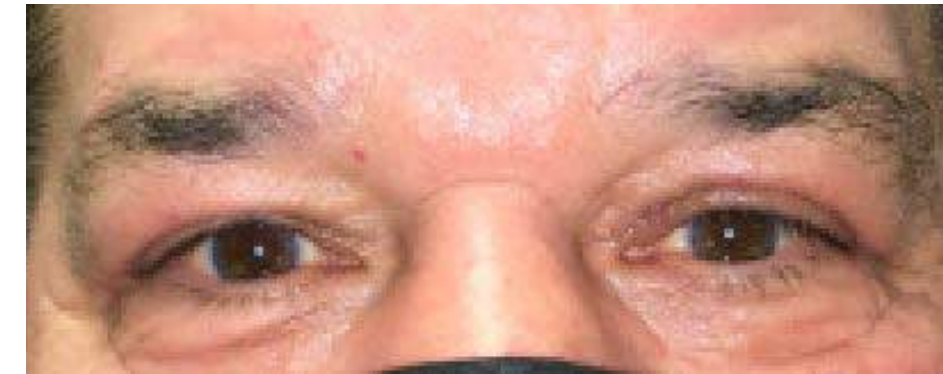
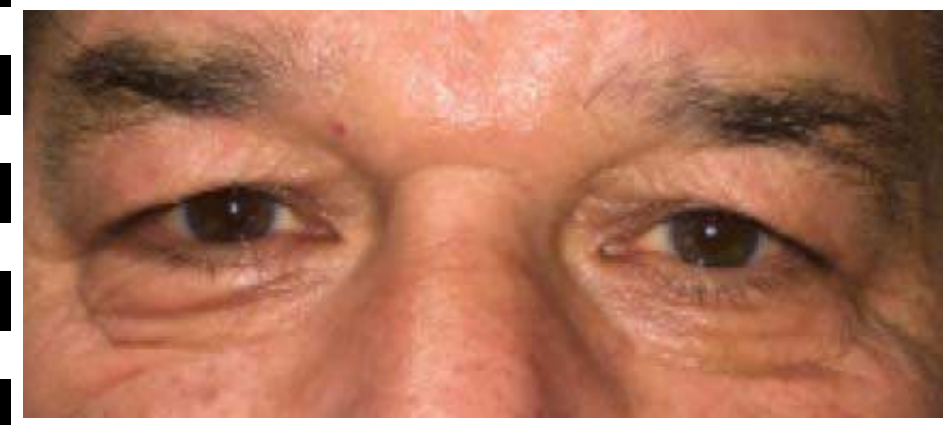
Before & Three Months After:
Upper Lid Blepharoplasty and Brow Lift



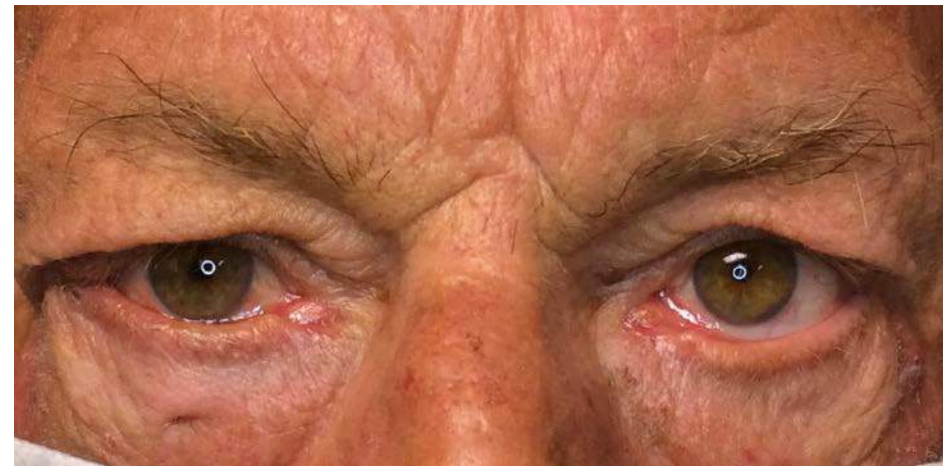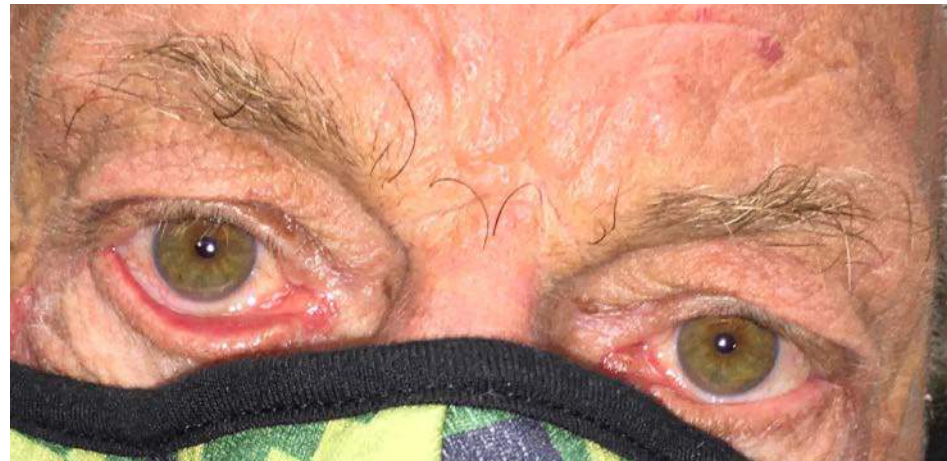Before & Three Months After:

Internal Ptosis Repair for Drooping Eyelids
Due to Myasthenia Gravis



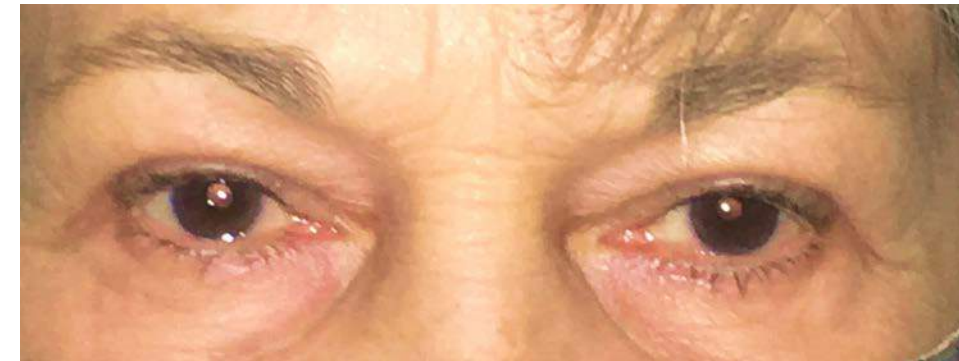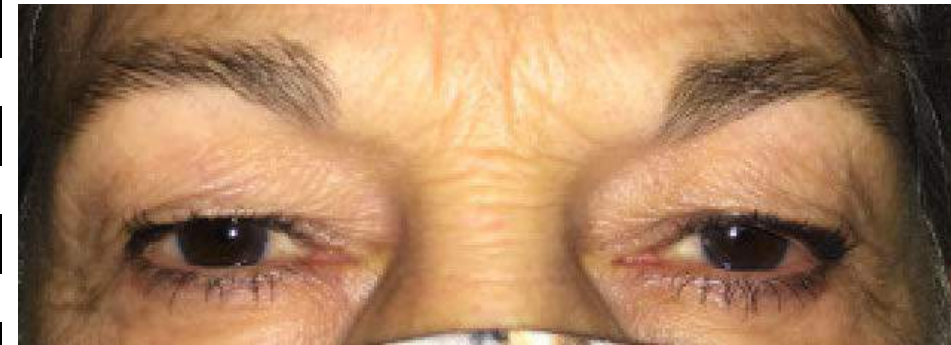Before & Three Months After:

Upper Lid Blepharoplasty and Brow Lift



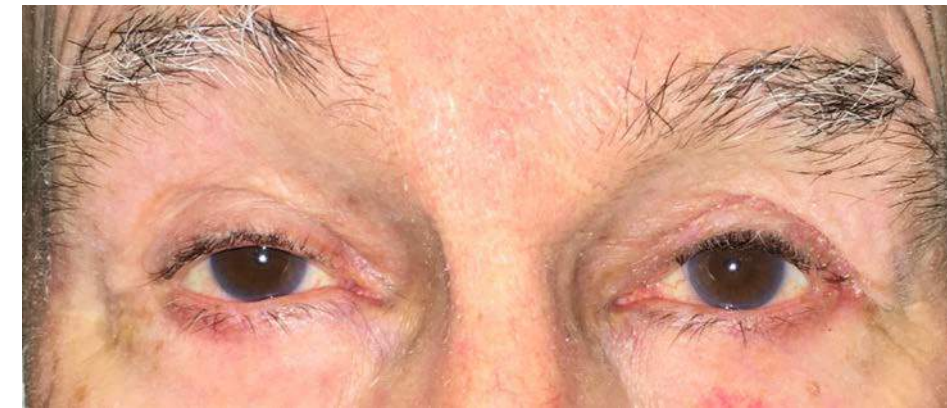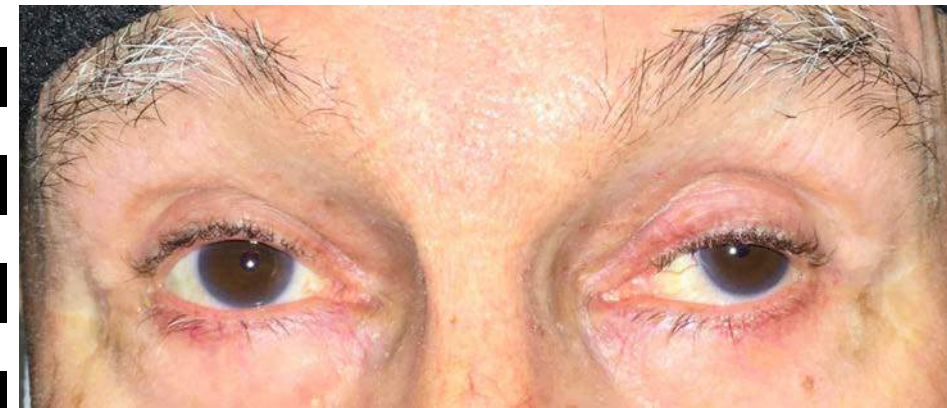
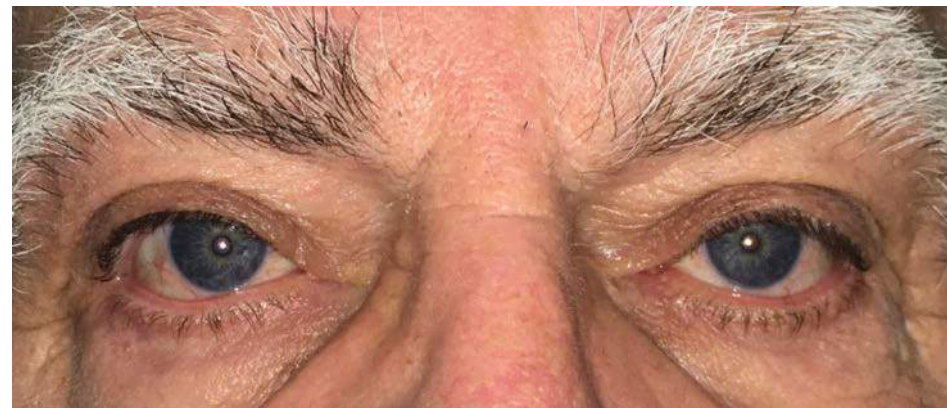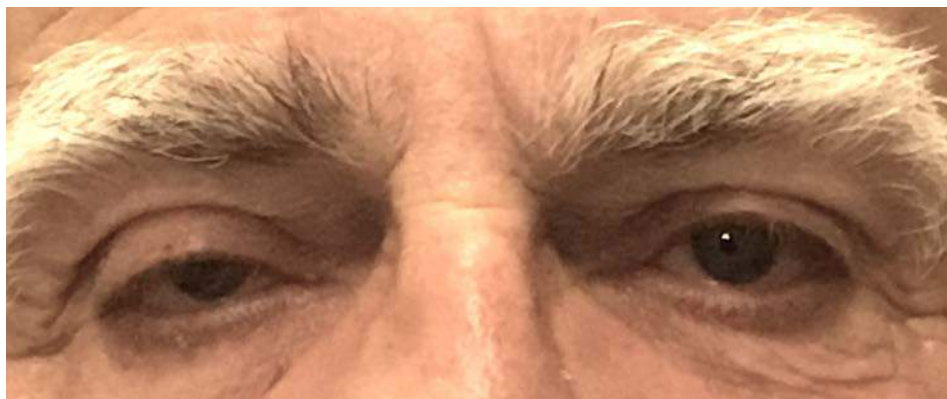Before & Two Weeks After:

Right Lower Lid Ectropion Repair,
Left Lower Eyelid Surgery Planned in Future



Before & One Month After:

Upper Lid Blepharoplasty

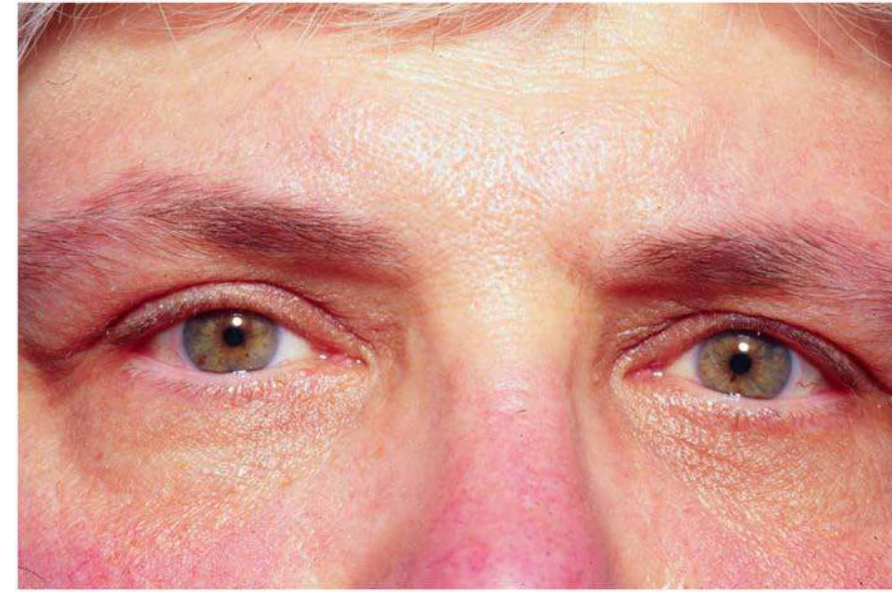
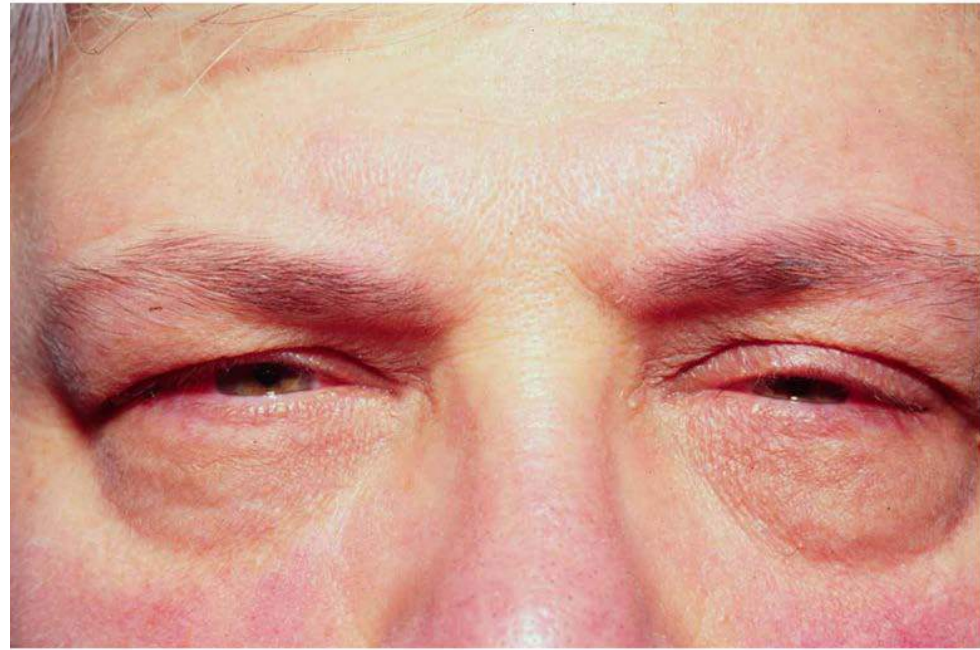
Before & One Month After:

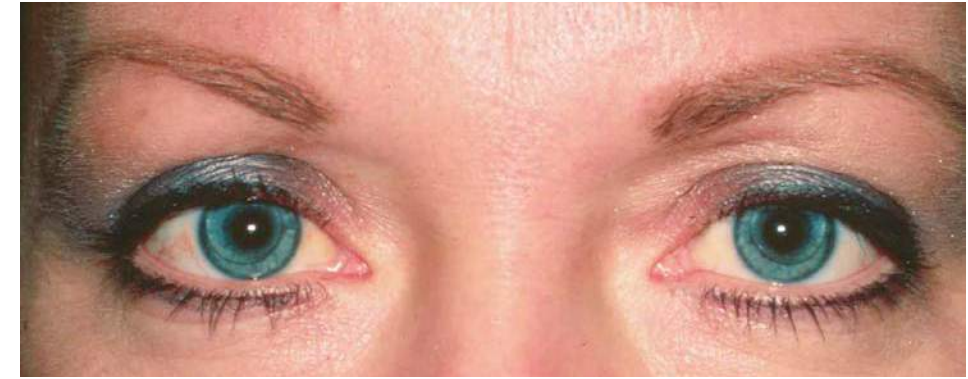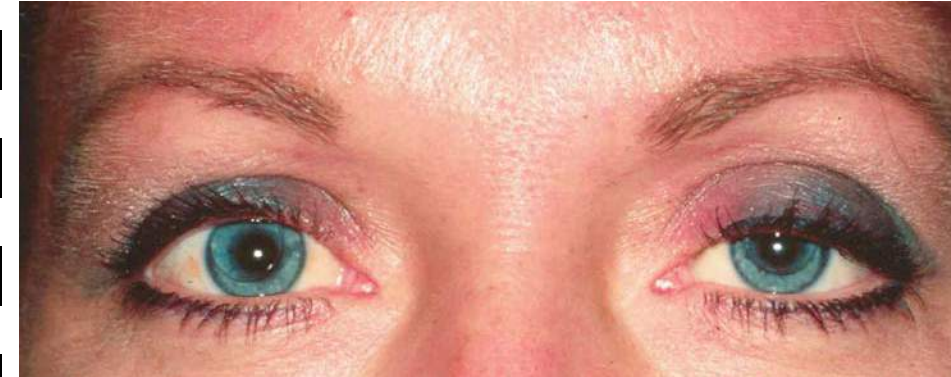Right Upper Eyelid Repair (Third Nerve Palsy)

Before & Two Months After:

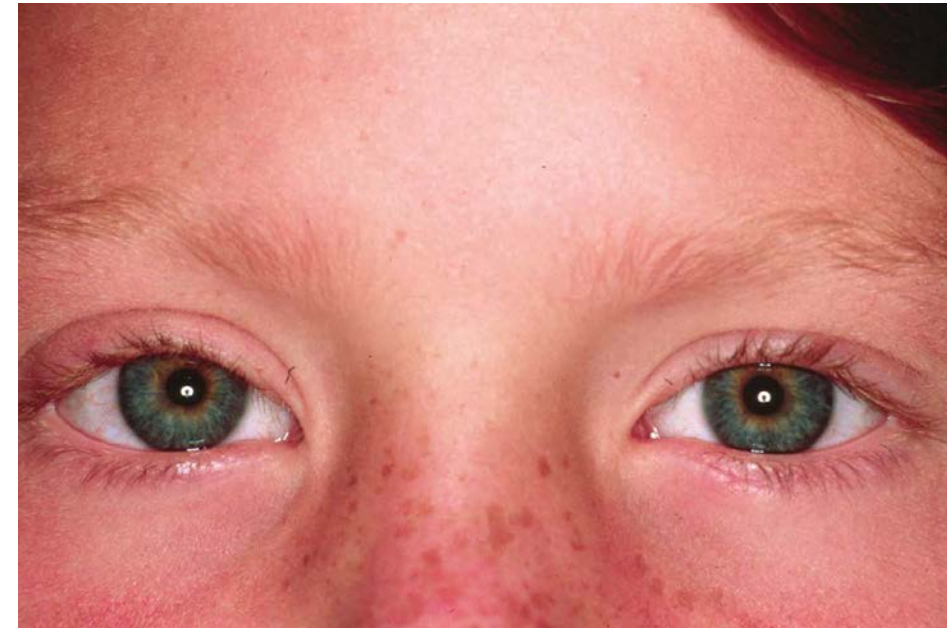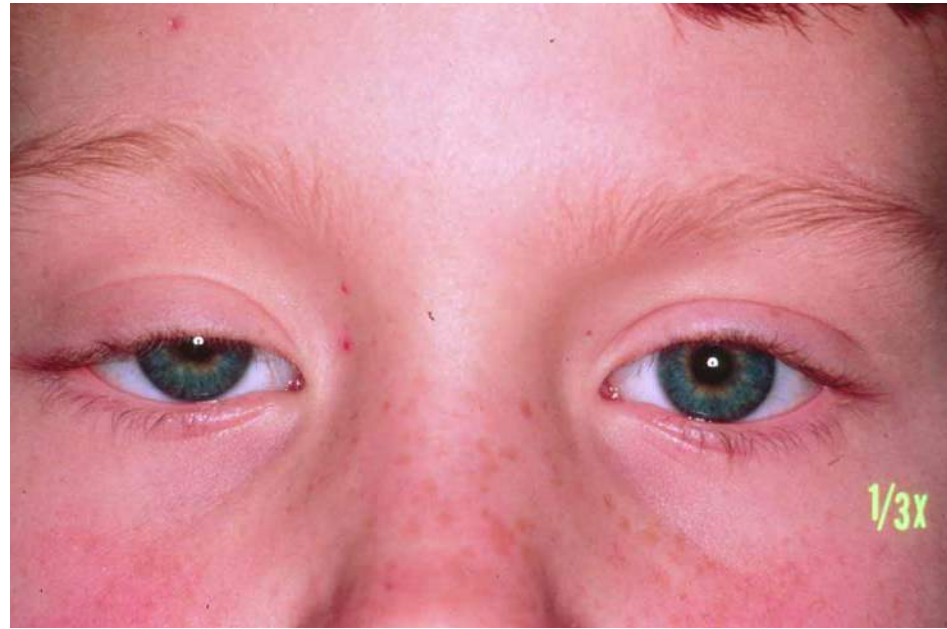Left External Ptosis Repair (Myasthenia Gravis)



Before & Two Months After: Left External
Ptosis Repair, Internal Brow Lift and
Blepharoplasty (Myasthenia Gravis)

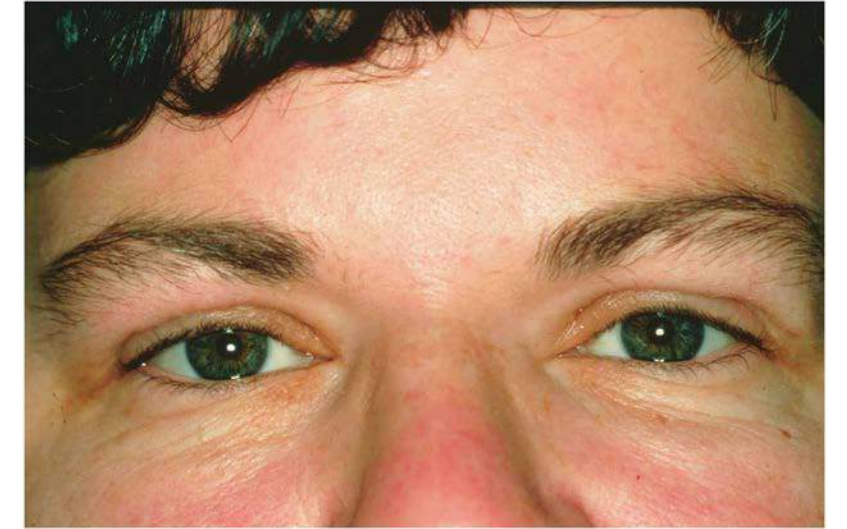
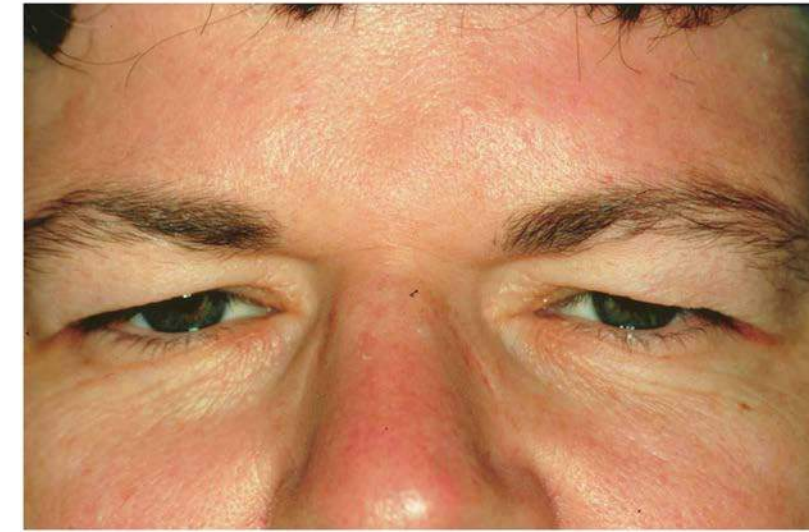
Before & After:
Left External Levator Tuck



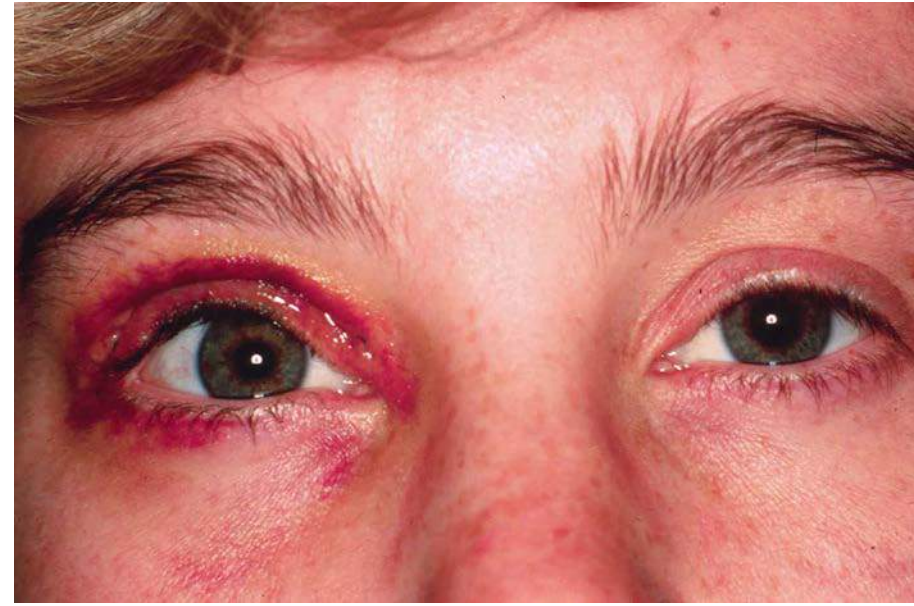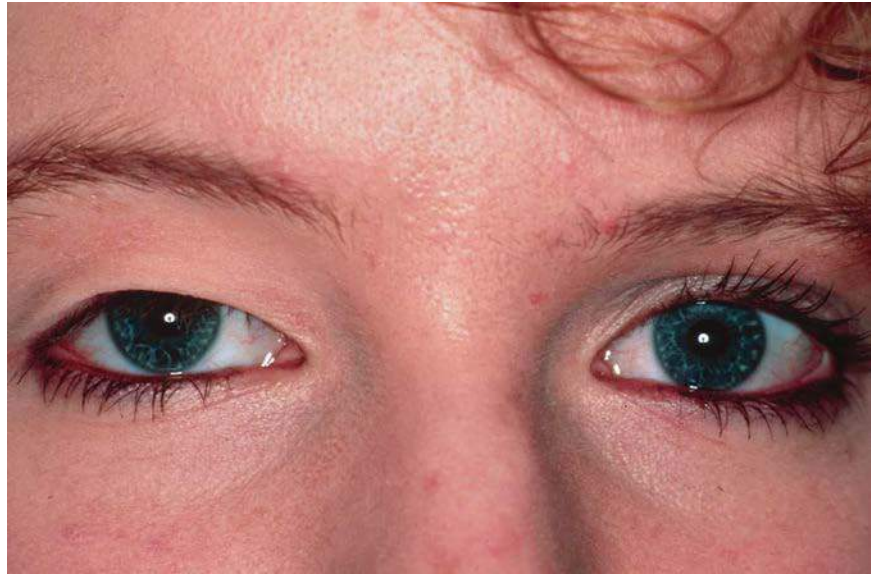
Before & After:

Unilateral Frontalis Sling For Congenital Ptosis

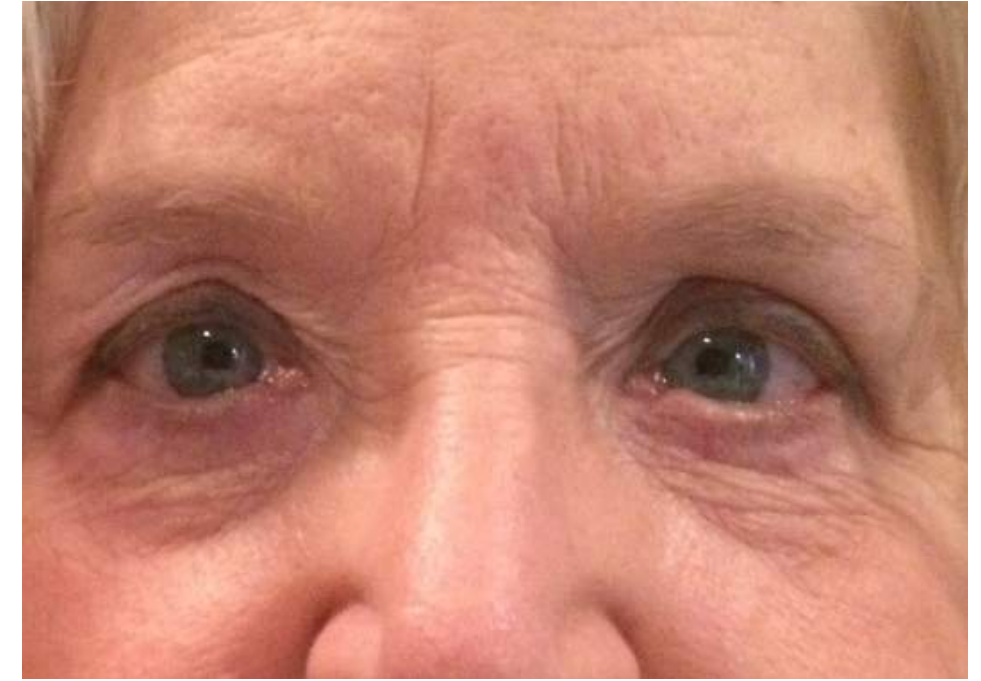
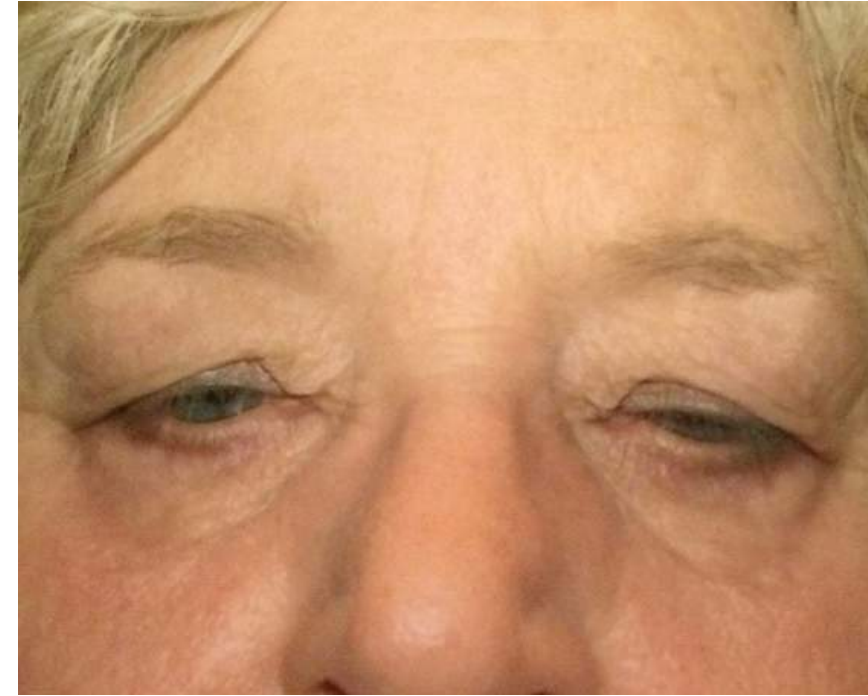
Before & After:

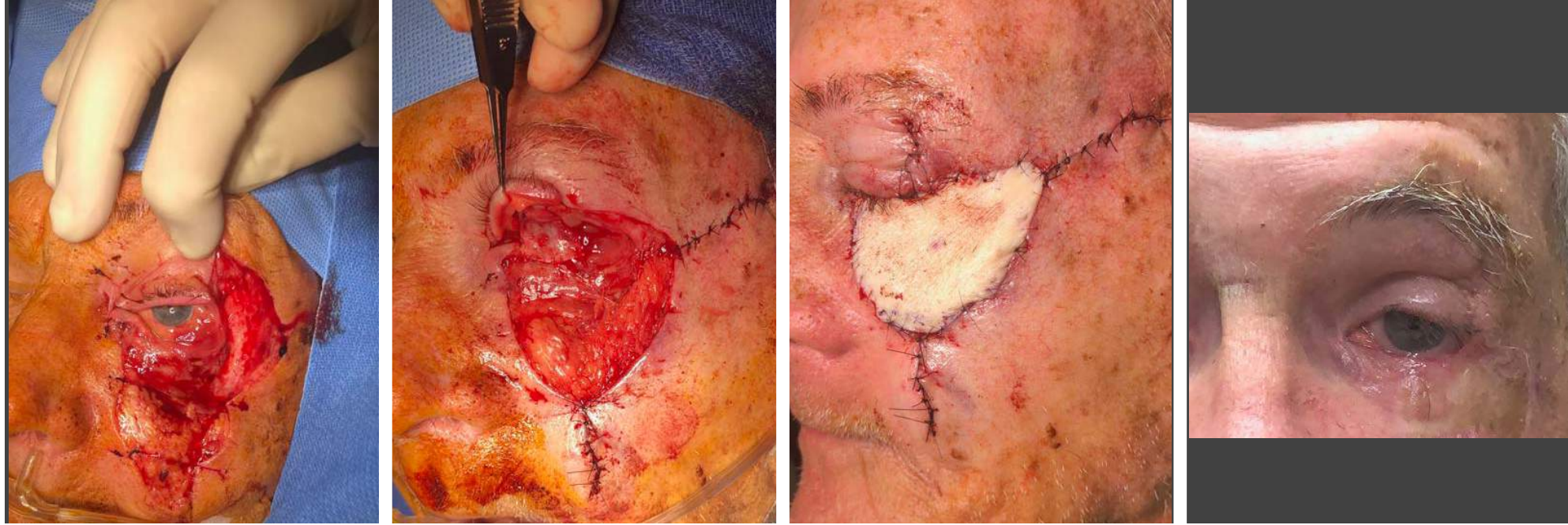Upper Lid Blepharoplasty and Brow Lift



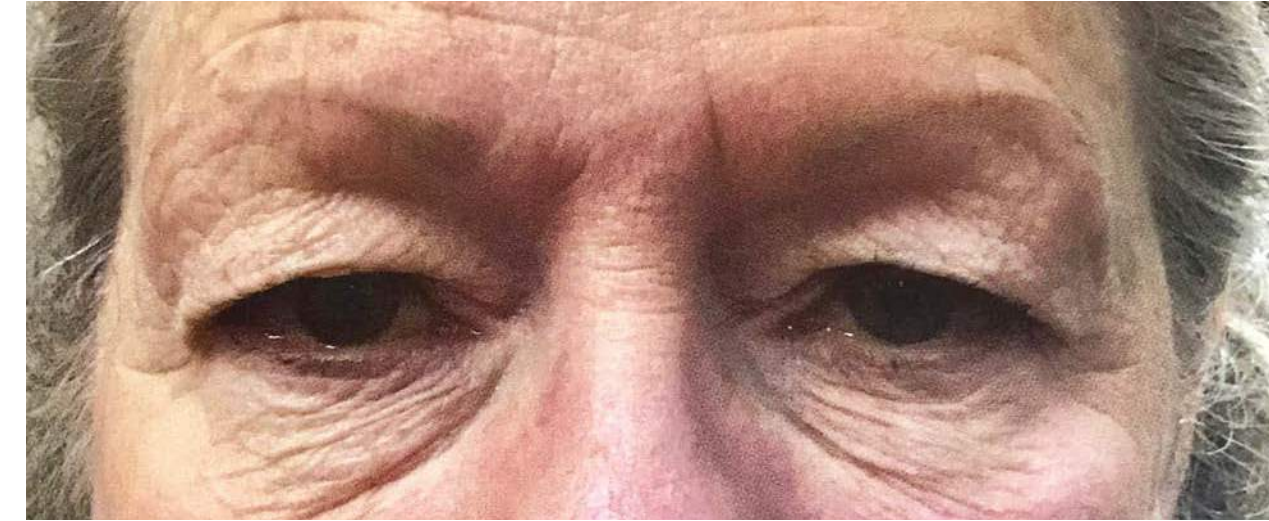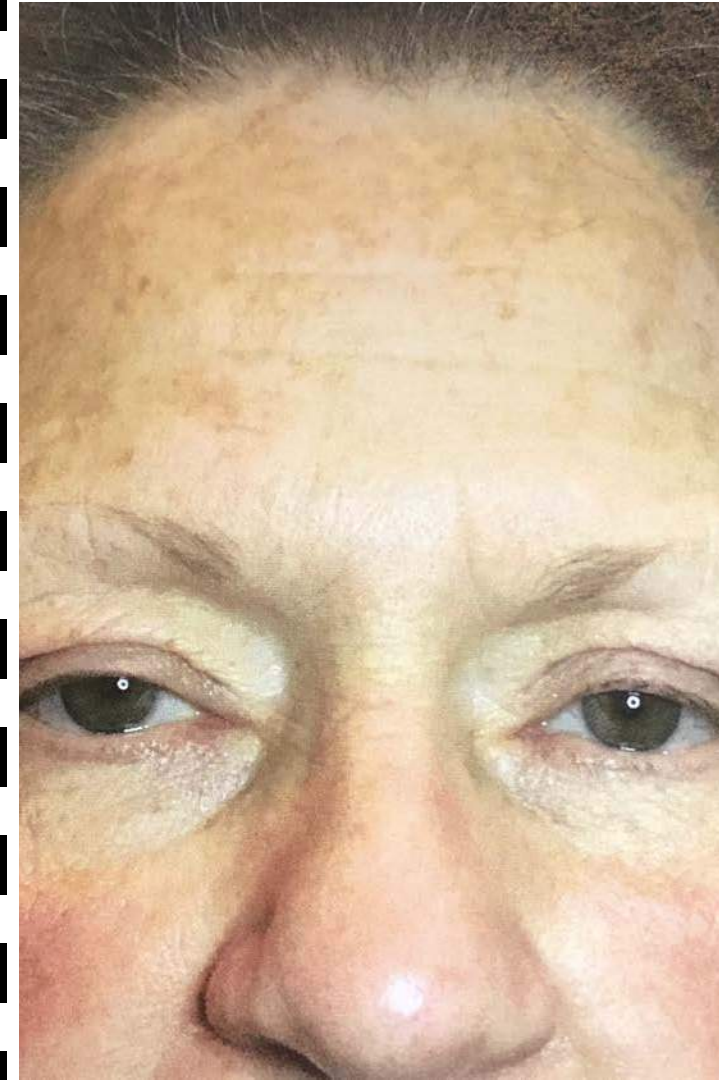Before & One Week After:
External Ptosis Repair for Congenital Ptosis



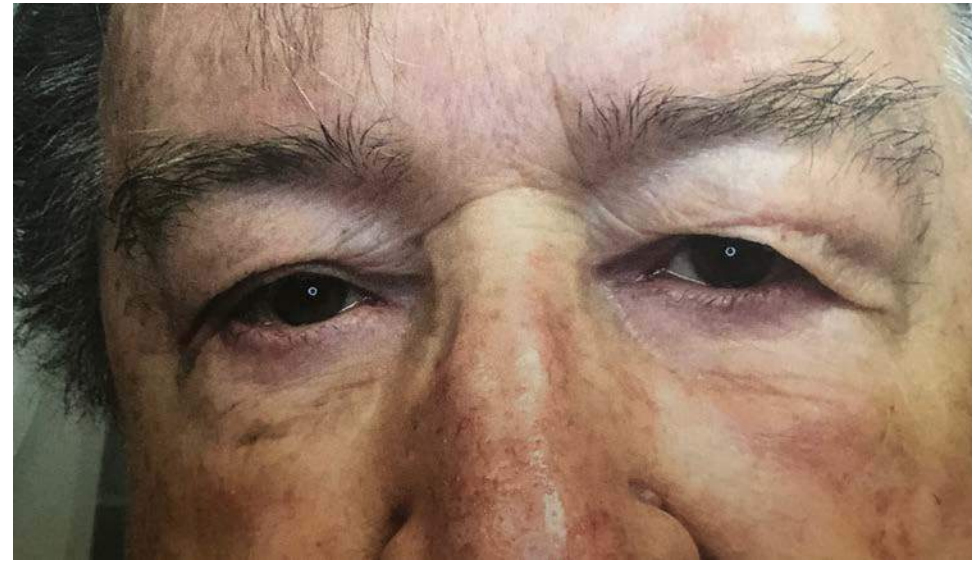
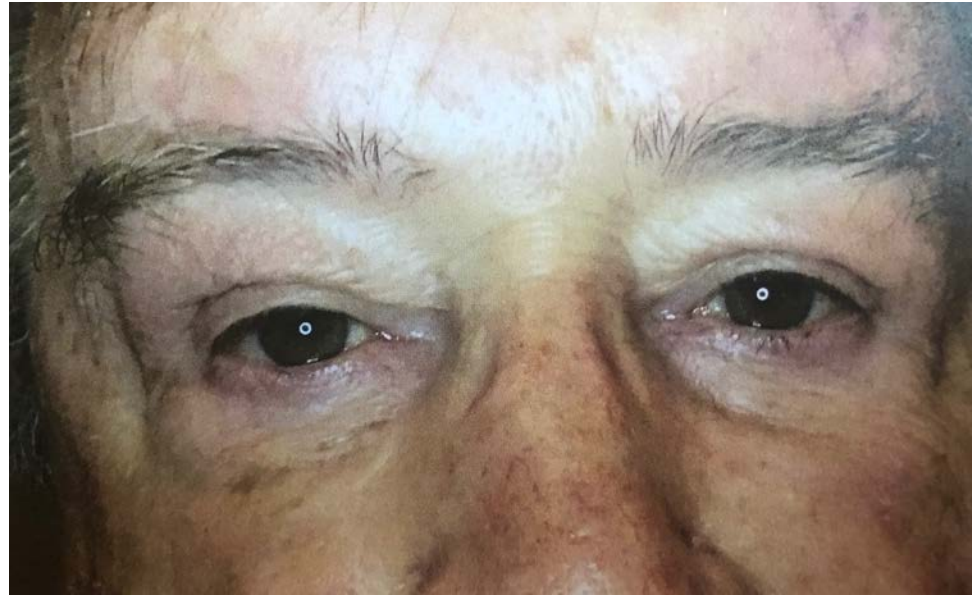Before & After:
Upper Eyelid Blepharoplasty



Before & After: MOHS Cancer Graft and Flap
Reconstruction for Basal Cell Carcinoma

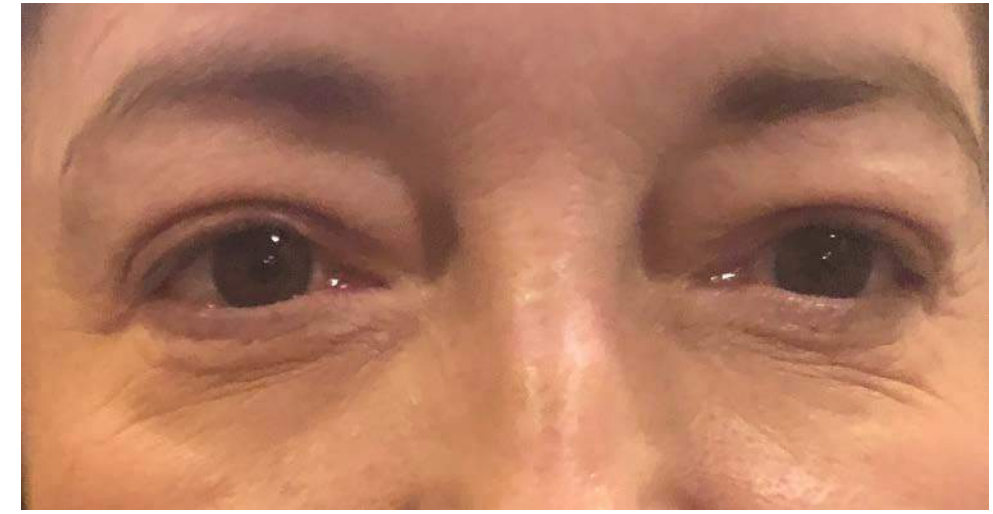
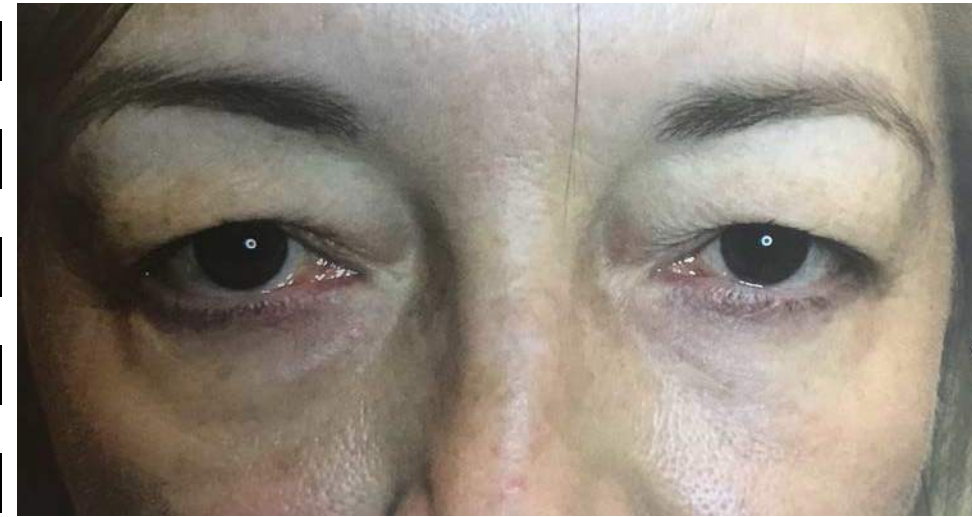
Before & After:
Upper and Lower Eyelid
Blepharoplasty



Before & After:

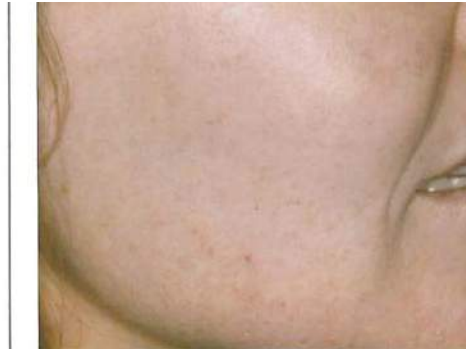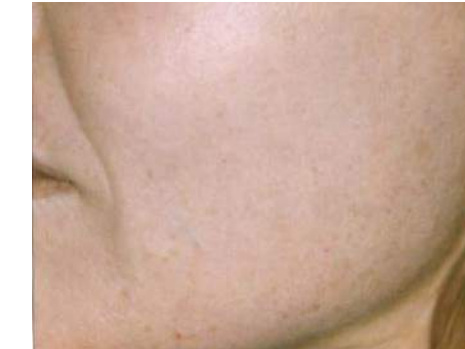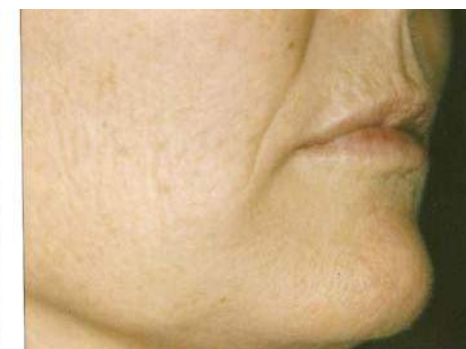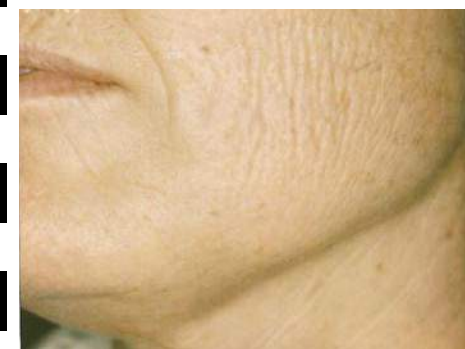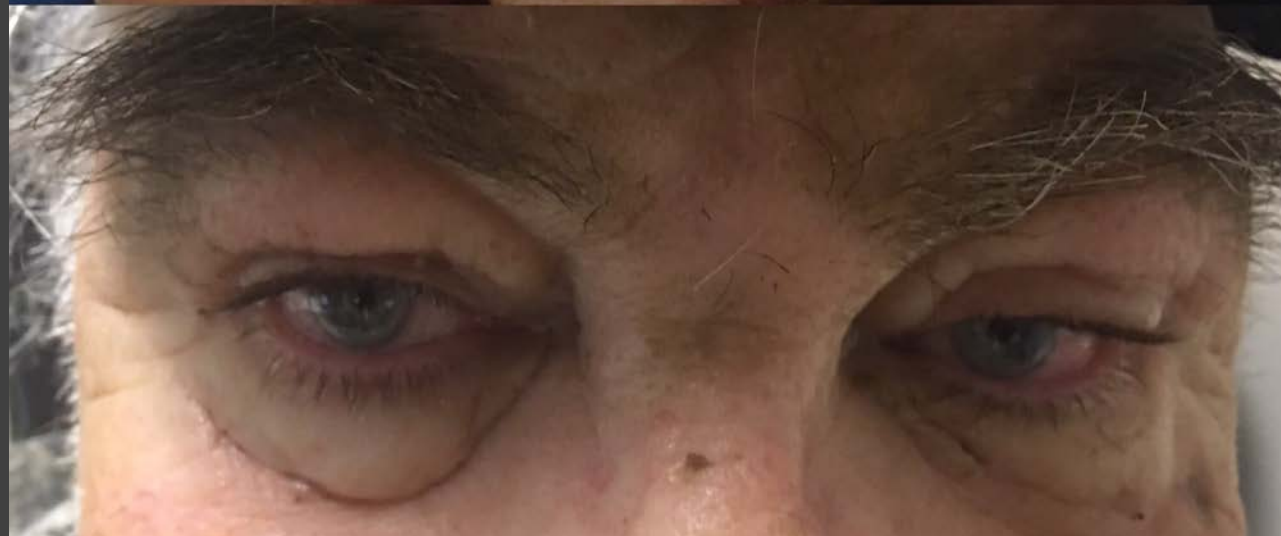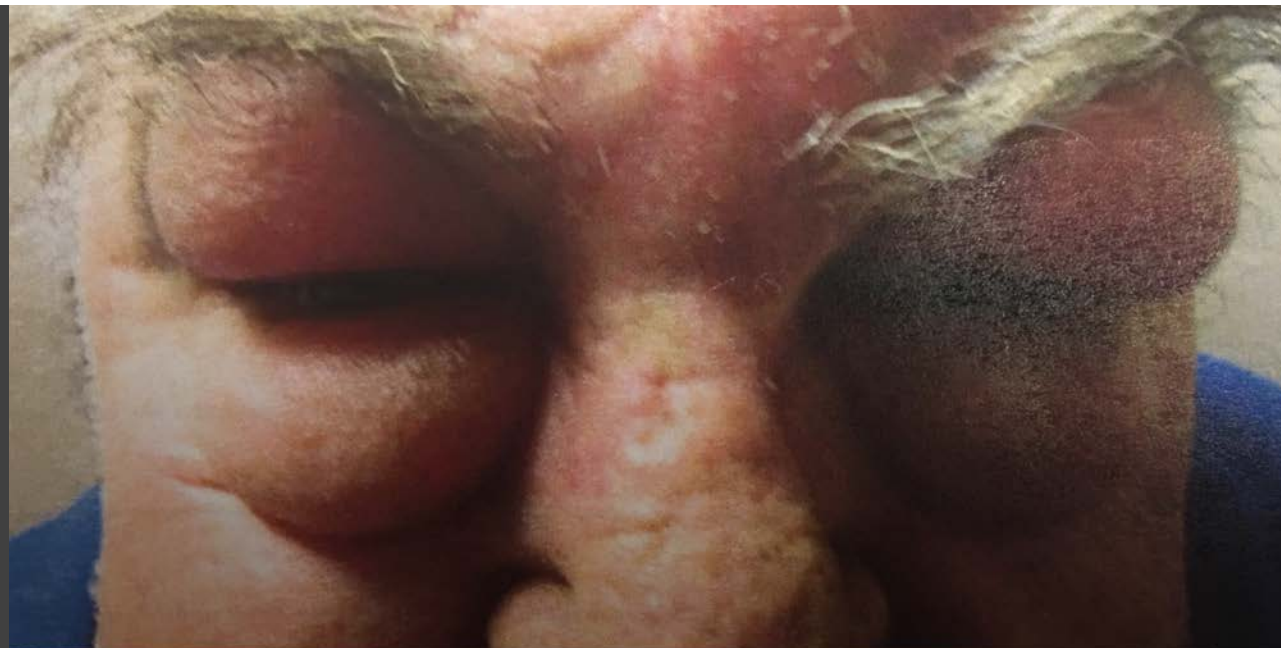
Upper Eyelid Blepharoplasty



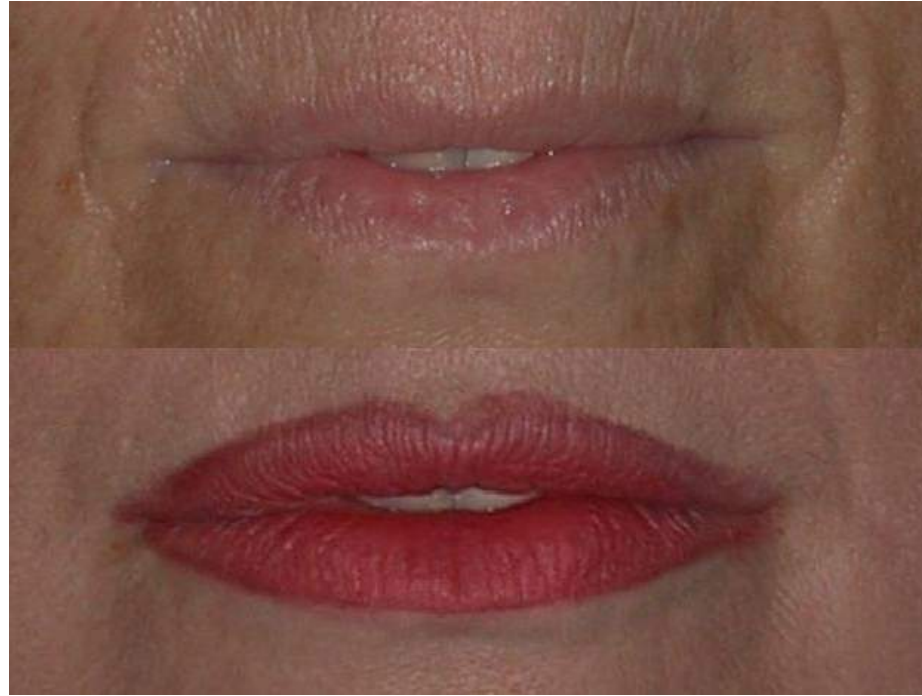Before & After:

Upper Eyelid Blepharoplasty

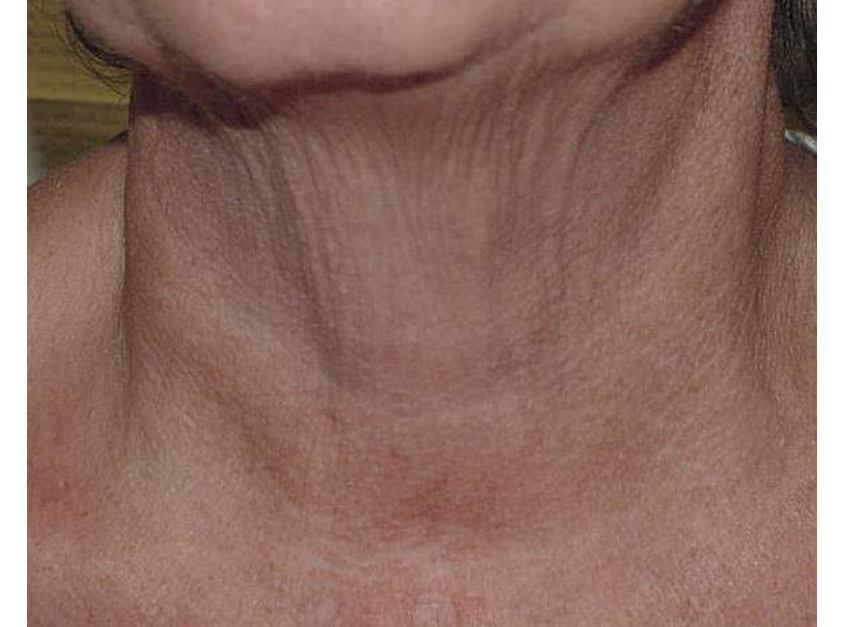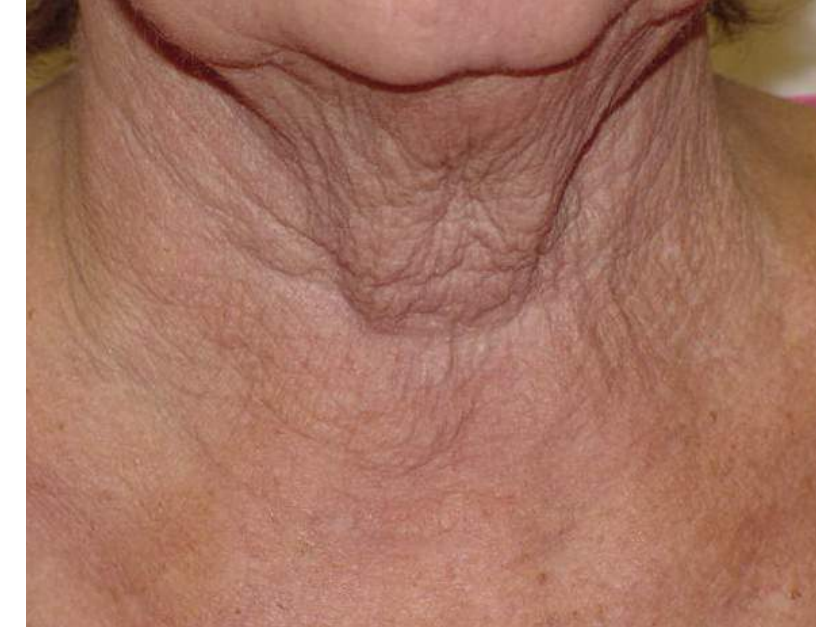Before & After:
Upper and
Lower Eyelid
Blepharoplasty
(Sleep Apnea)



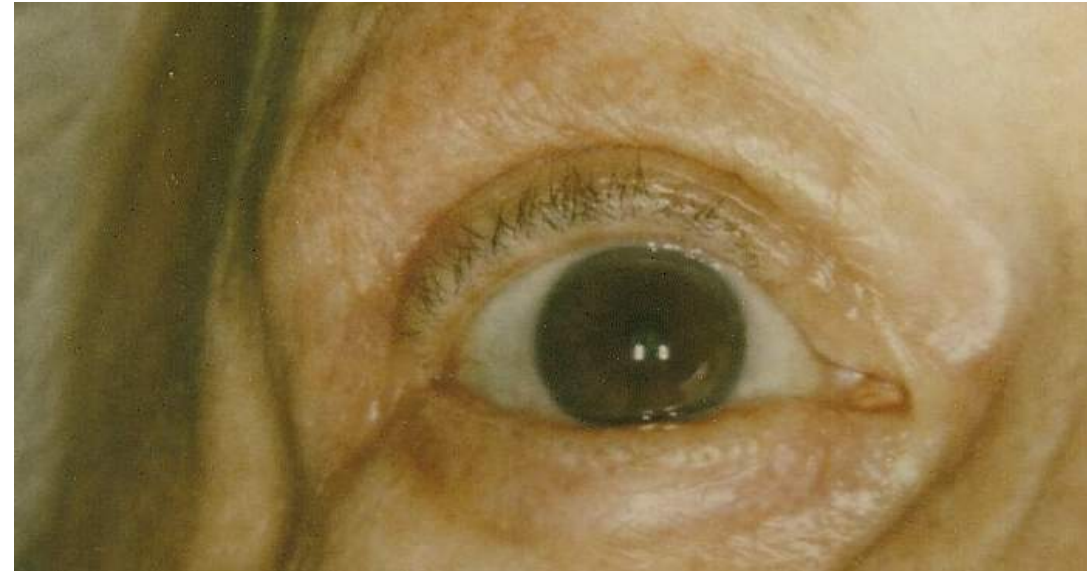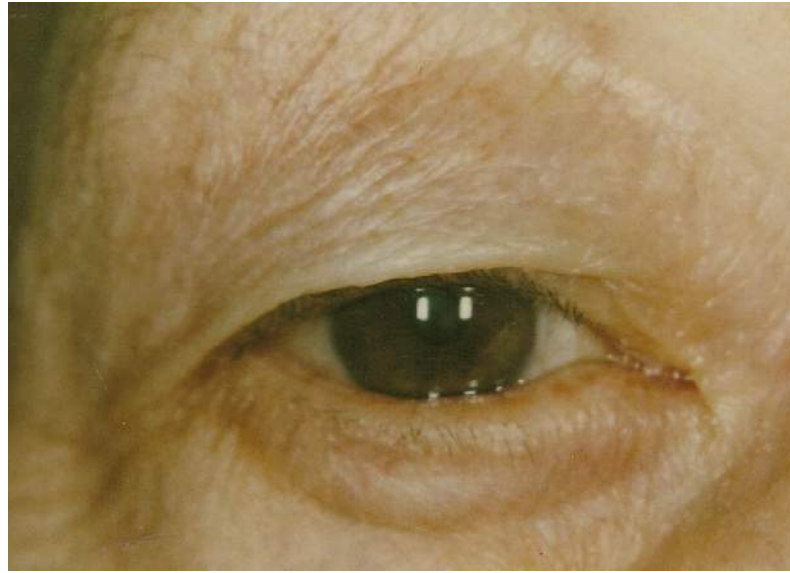
Before & One Month After:
Skin Resurfacing



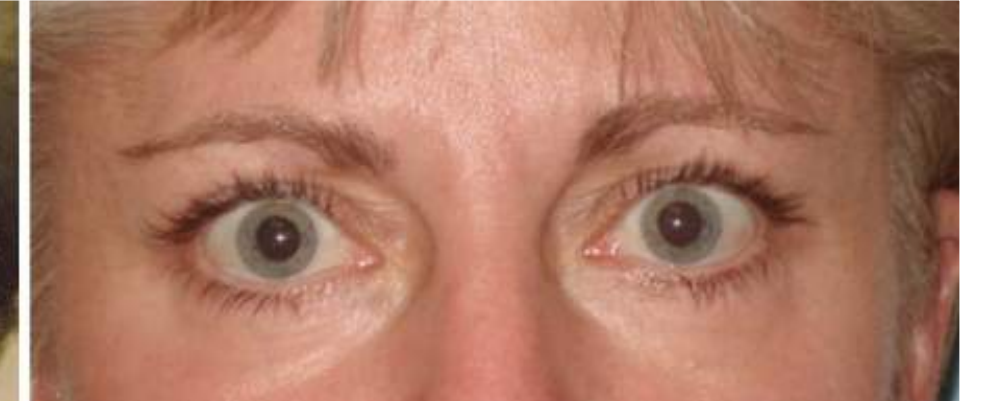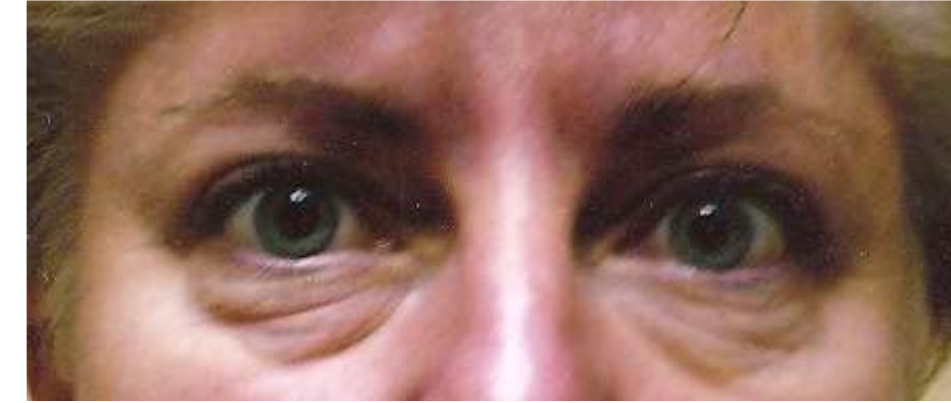Before & One Month After:
Botox Lip Flip and Restylane Refyne



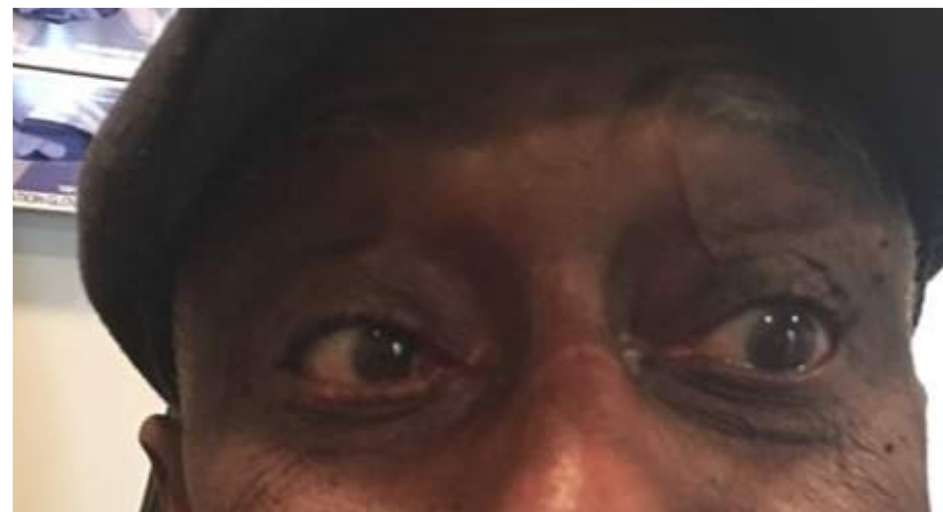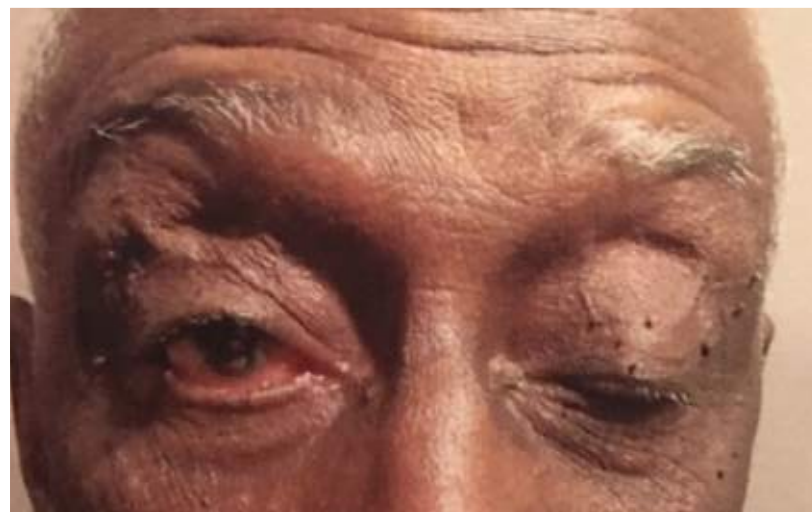Before & Three Months After:
Skin Resurfacing x 3



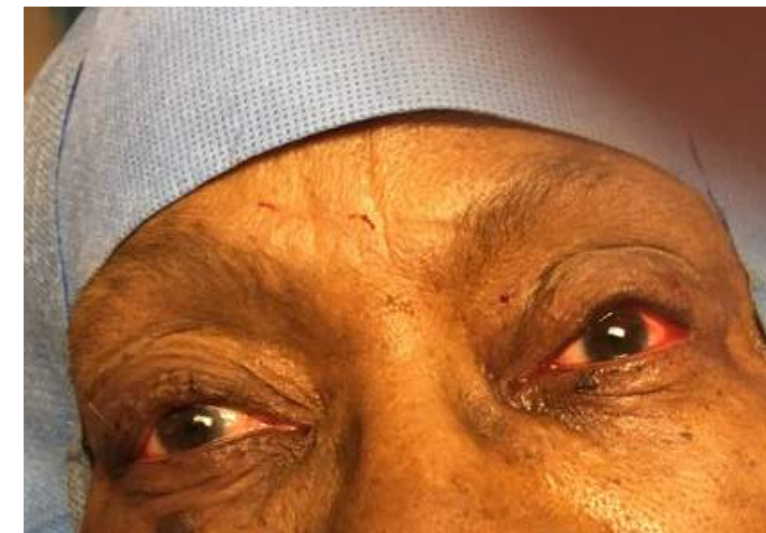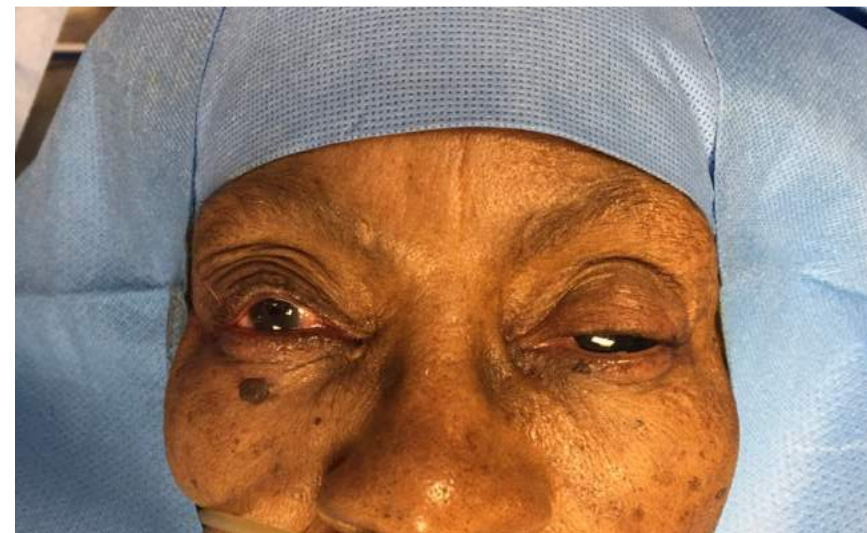Before & After: Upper Lid Blepharoplasty
and External Levator Muscle Lift



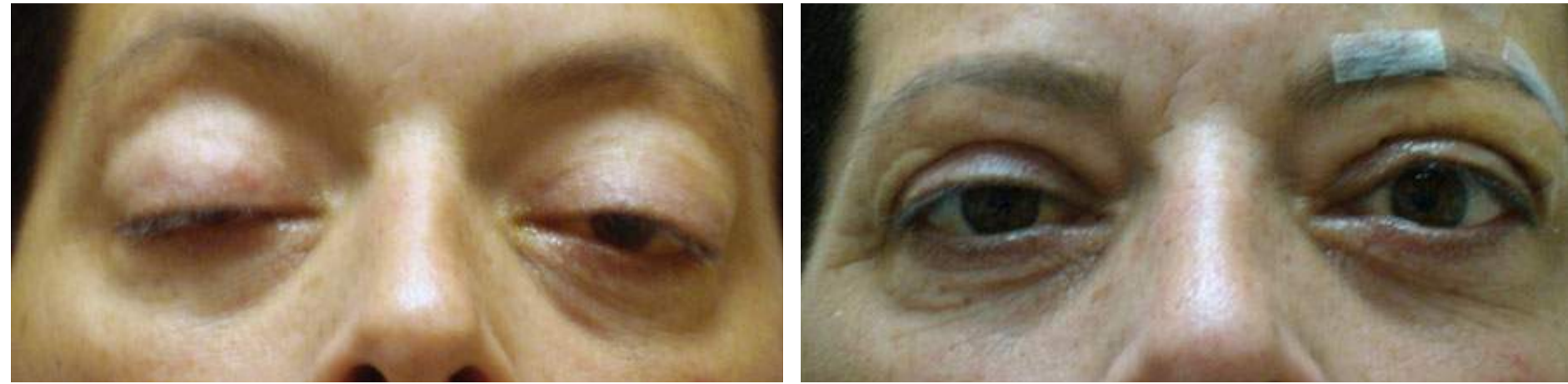
Before & After:
Lower Lid Blepharoplasty & Skin Resurfacing



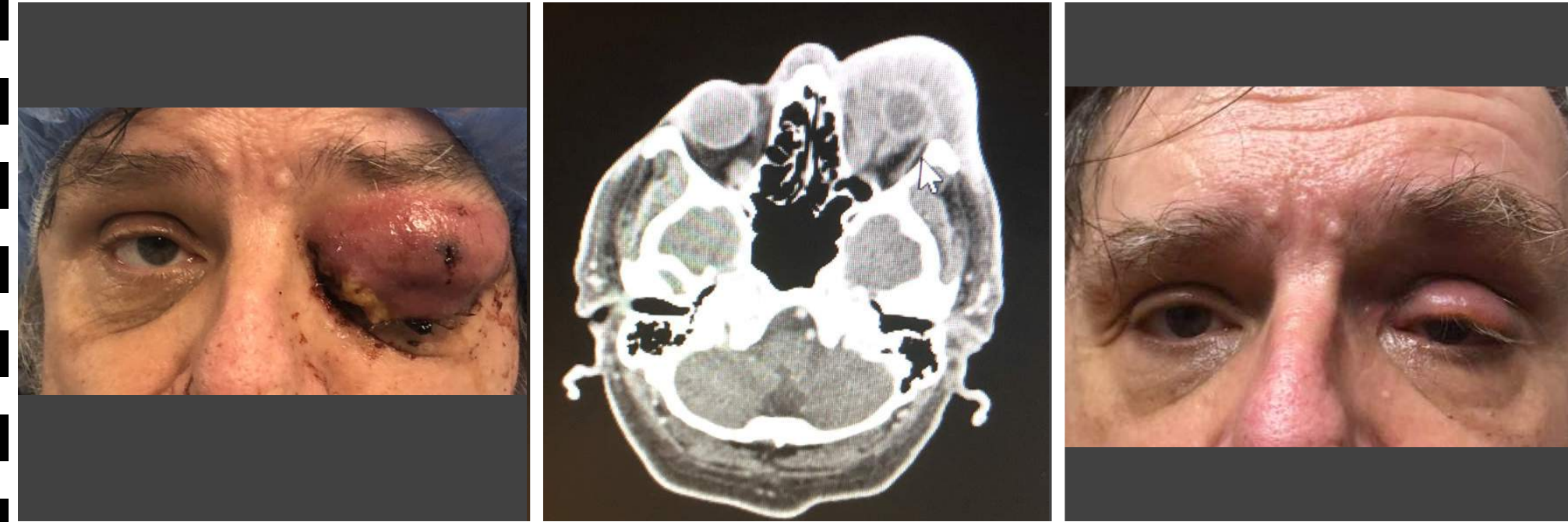
Before & After: Frontalis Sling for
Post-Traumatic Left Upper Eyelid Ptosis



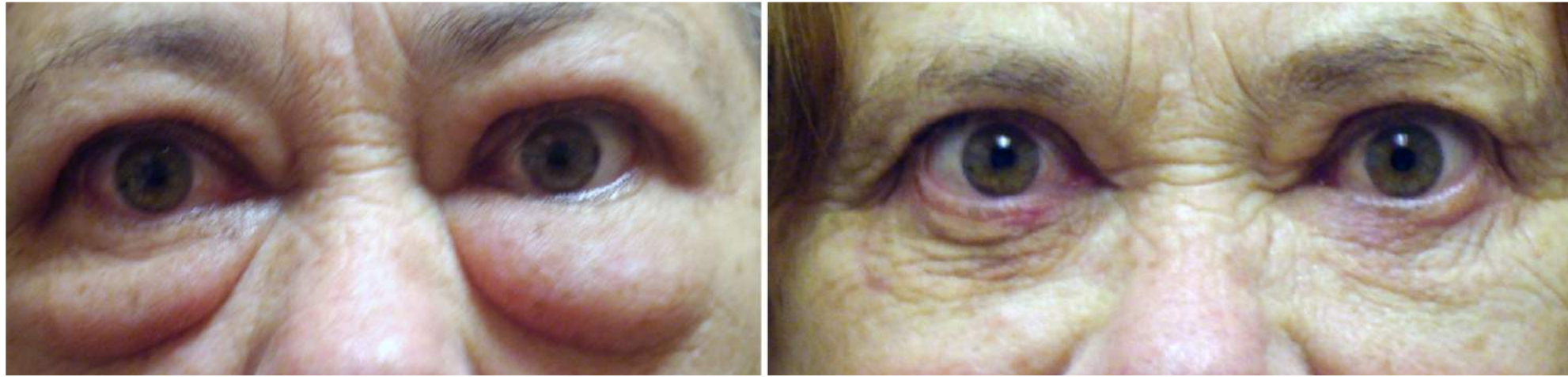Before & Immediately After:
(in operating room) Internal Ptosis Repair



Before & After: One Week Post-Op
Frontalis Sling for Myasthenia Gravis

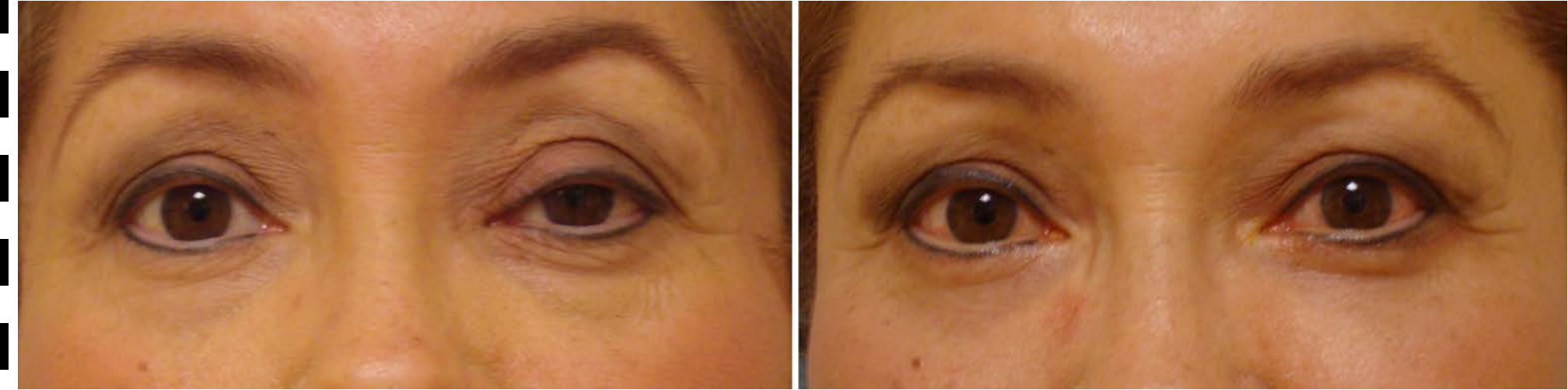

Before & Two Weeks After:
Orbital Abscess Drainage (MRSA infection)



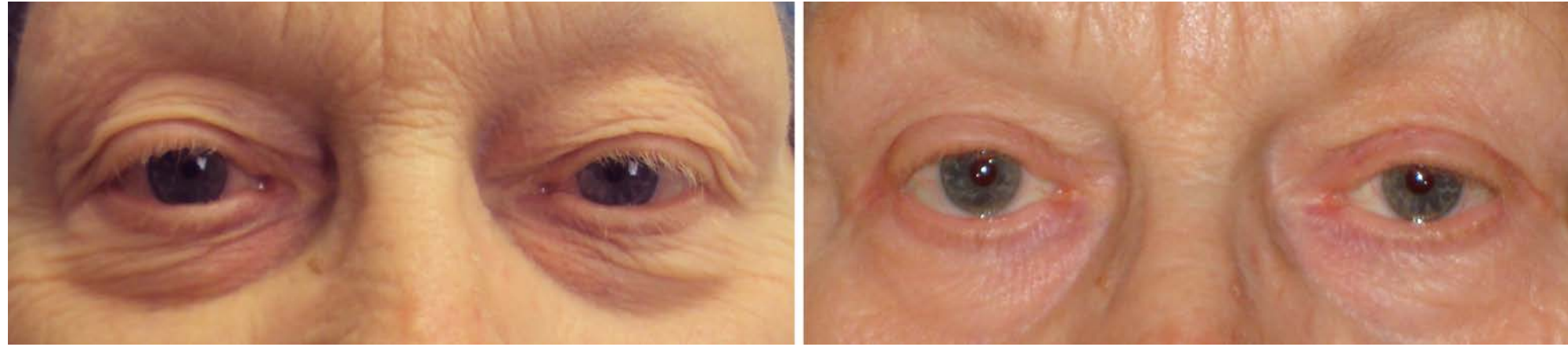Before & After:

Thyroid Eye Disease Decompression



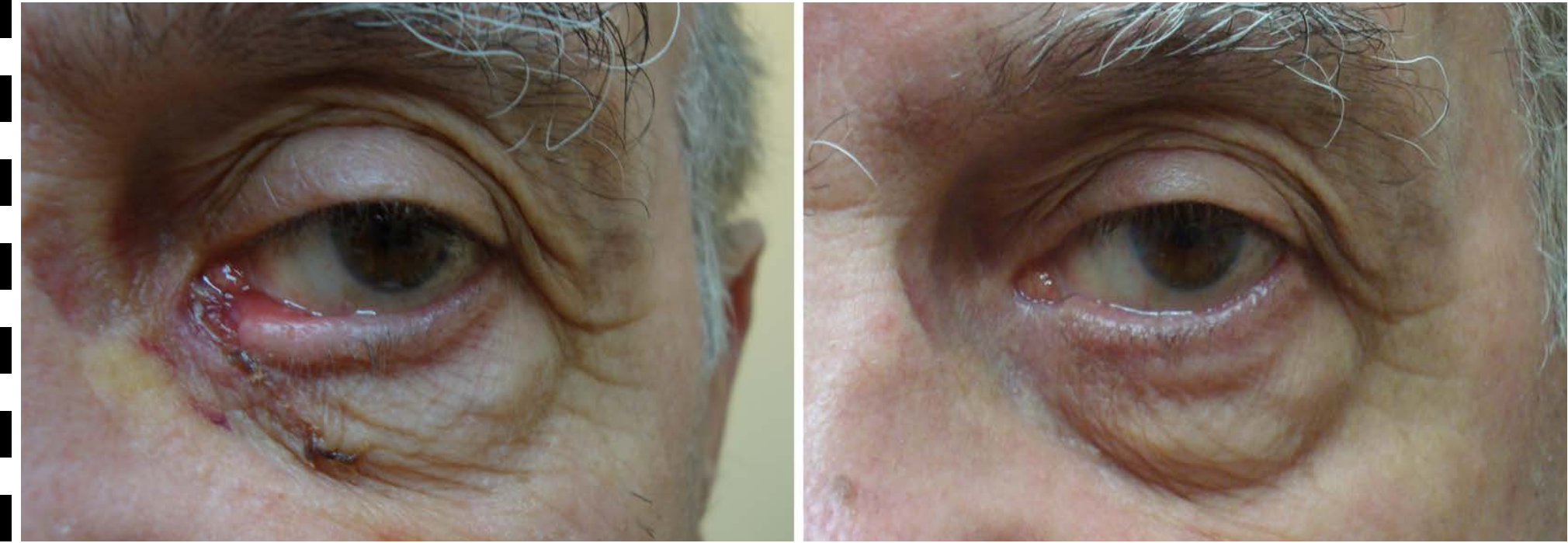
Before & After:

Internal Ptosis Repair Left Eye

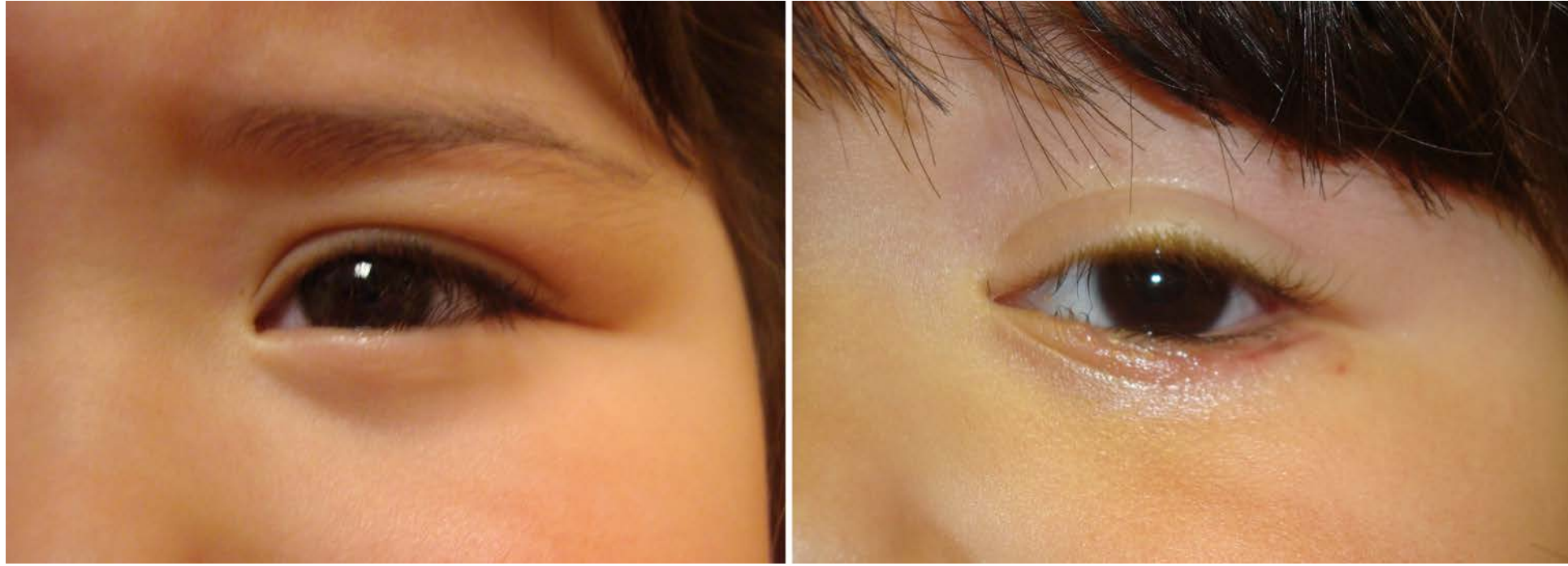

Before & After:

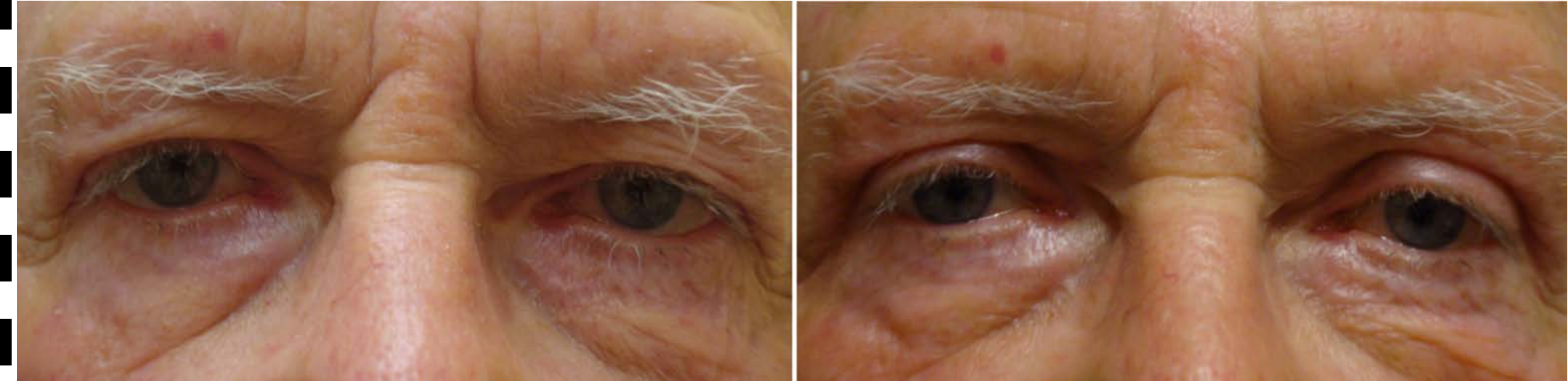Upper and Lower Lid Blepharoplasty



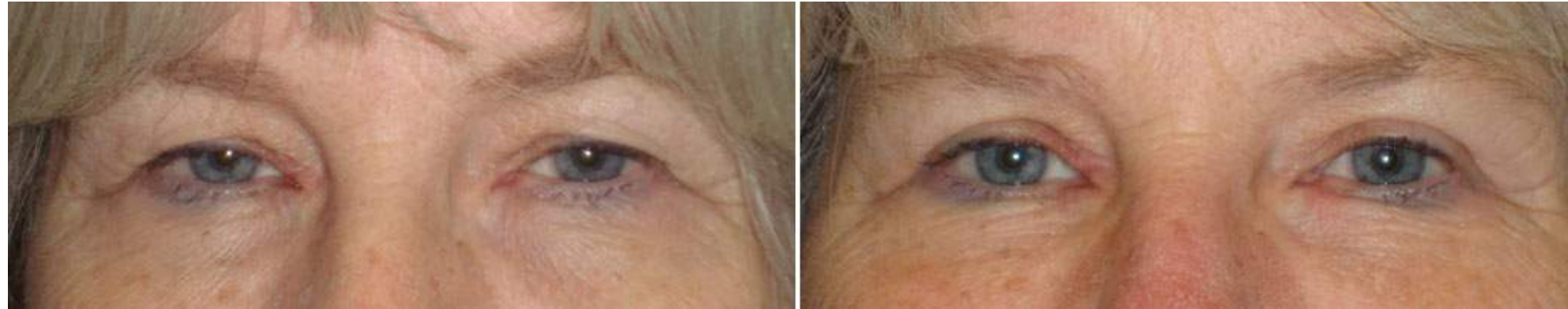Before & After: Left Lower Eyelid Excision
of Cancer and Reconstruction



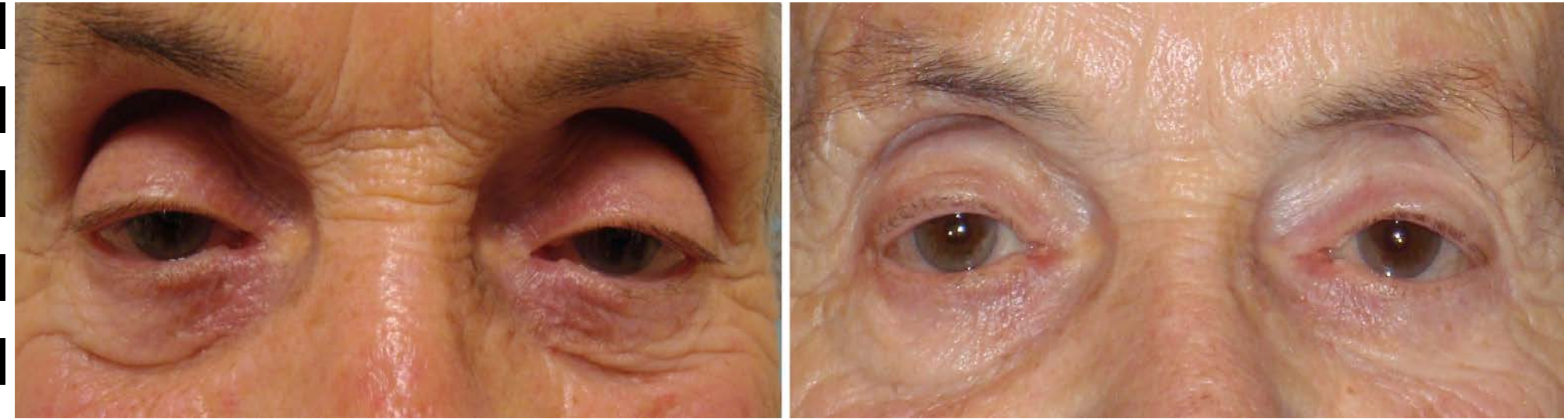
Before & After:
Left Entropion Repair



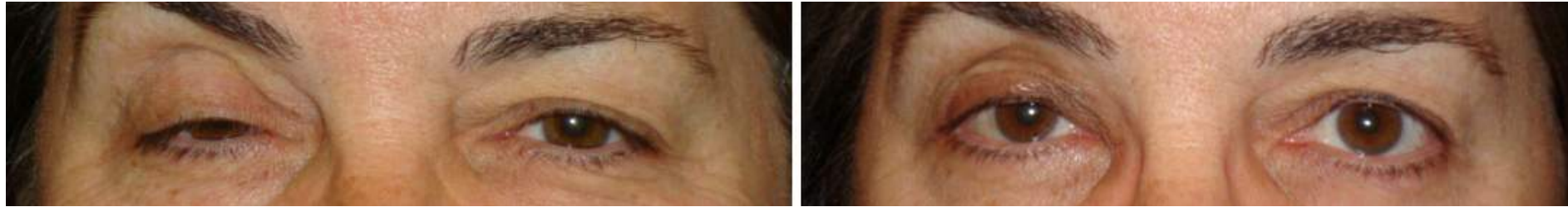Before & After:
Upper Eyelid Blepharoplasty



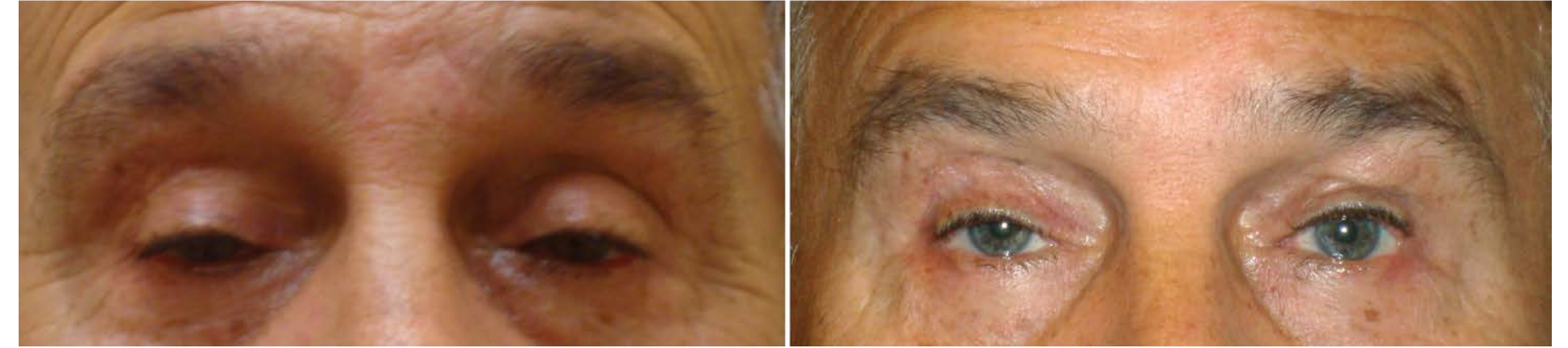Before & After:
Upper Lid Blepharoplasty



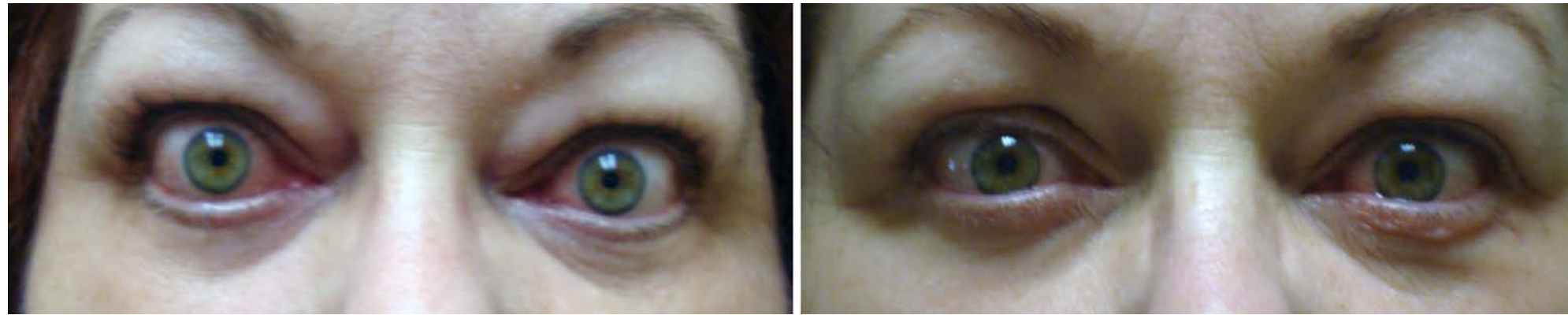Before & After:
Internal Ptosis Repair



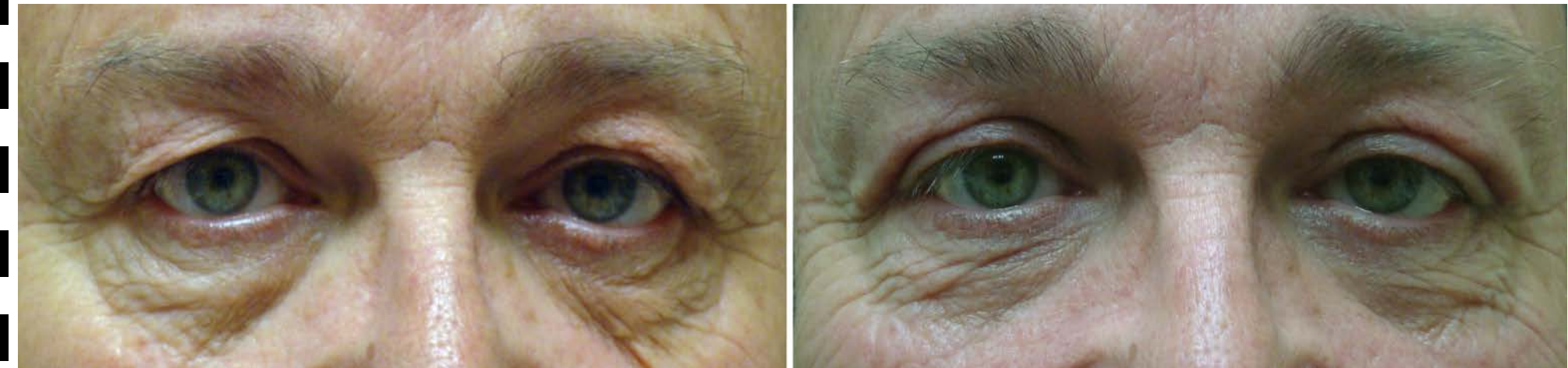Before & After: External Ptosis Repair,
Right Eye (Myasthenia Gravis)



Before & After:
Frontalis Sling for CPEO (Chronic
Progressive External Ophthalmoplegia)



Before & After: Eyelid Retraction Repair
for TED (Thyroid Eye Disease)



Before & After:
Upper Eyelid Blepharoplasty



Kimberly Cockerham, MD



C: 650-804-9270

O: 619-810-1275

F: 619-215-0404



CockerhamMD@gmail.com



CockerhamMD.com

